

**EXTREME
ULTRASOUND
CASES**

Jailyn Avila

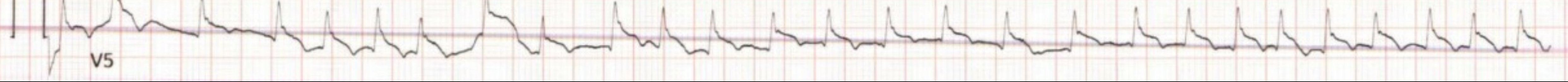
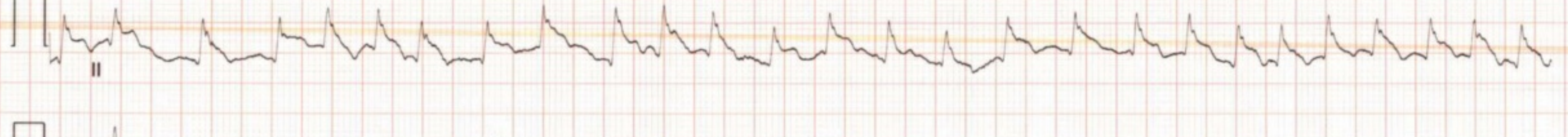
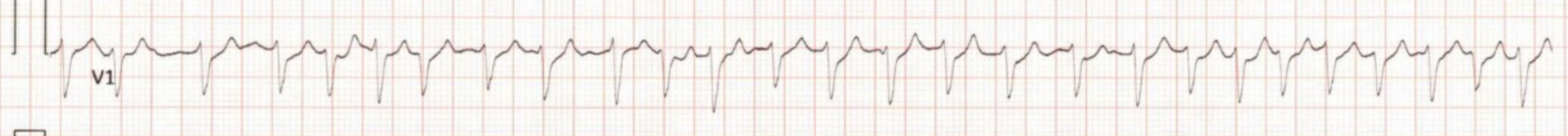
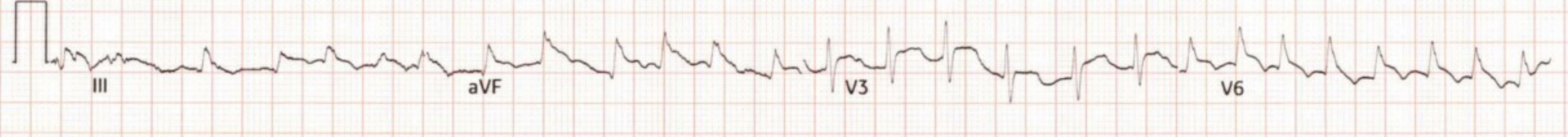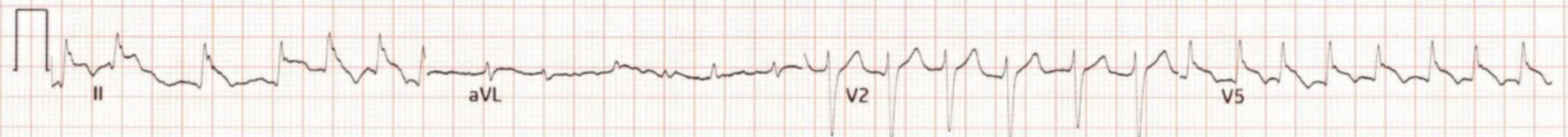
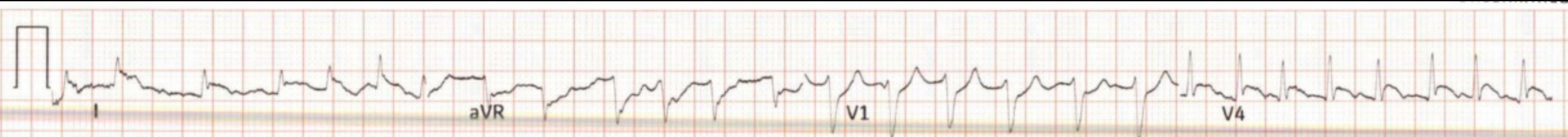
COI: Butterfly (former)

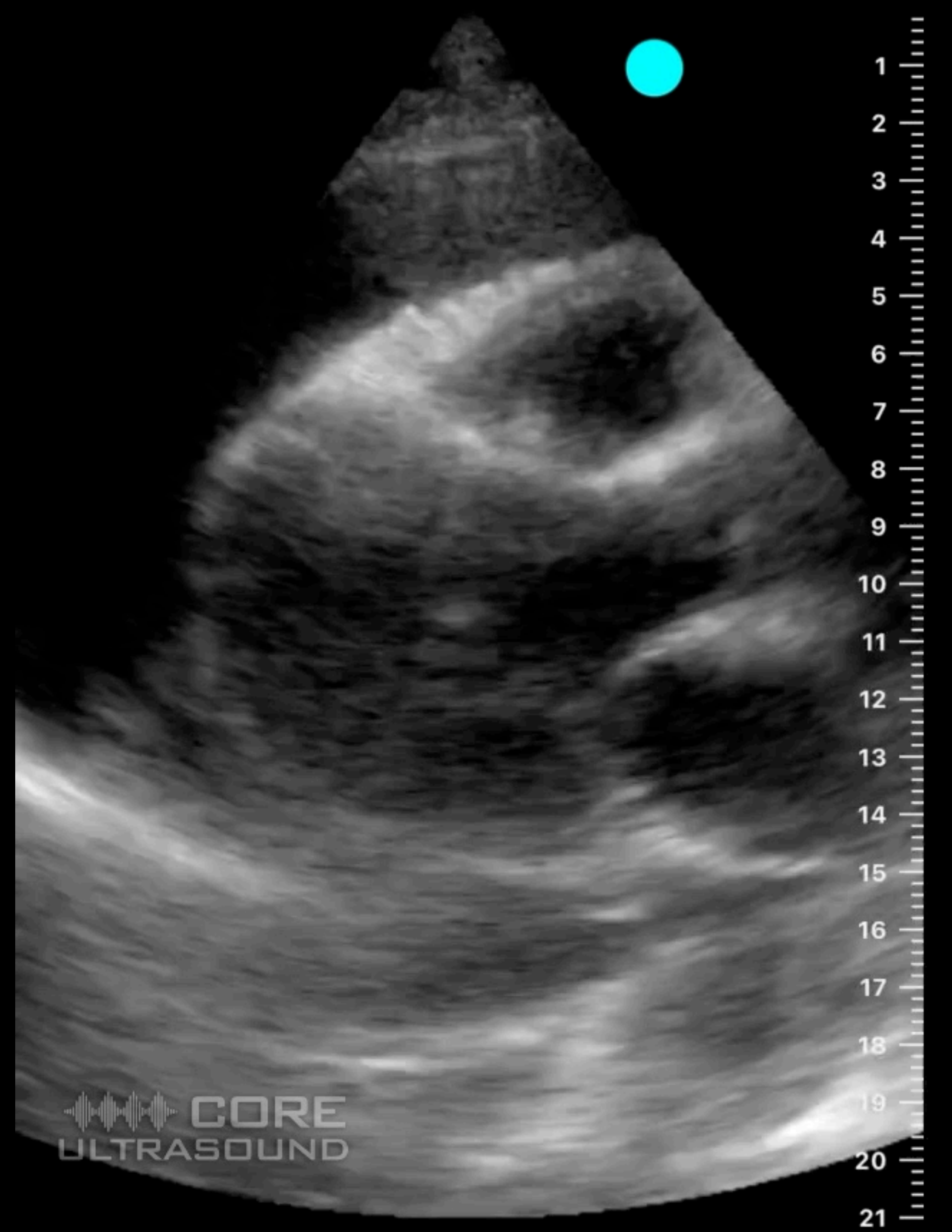
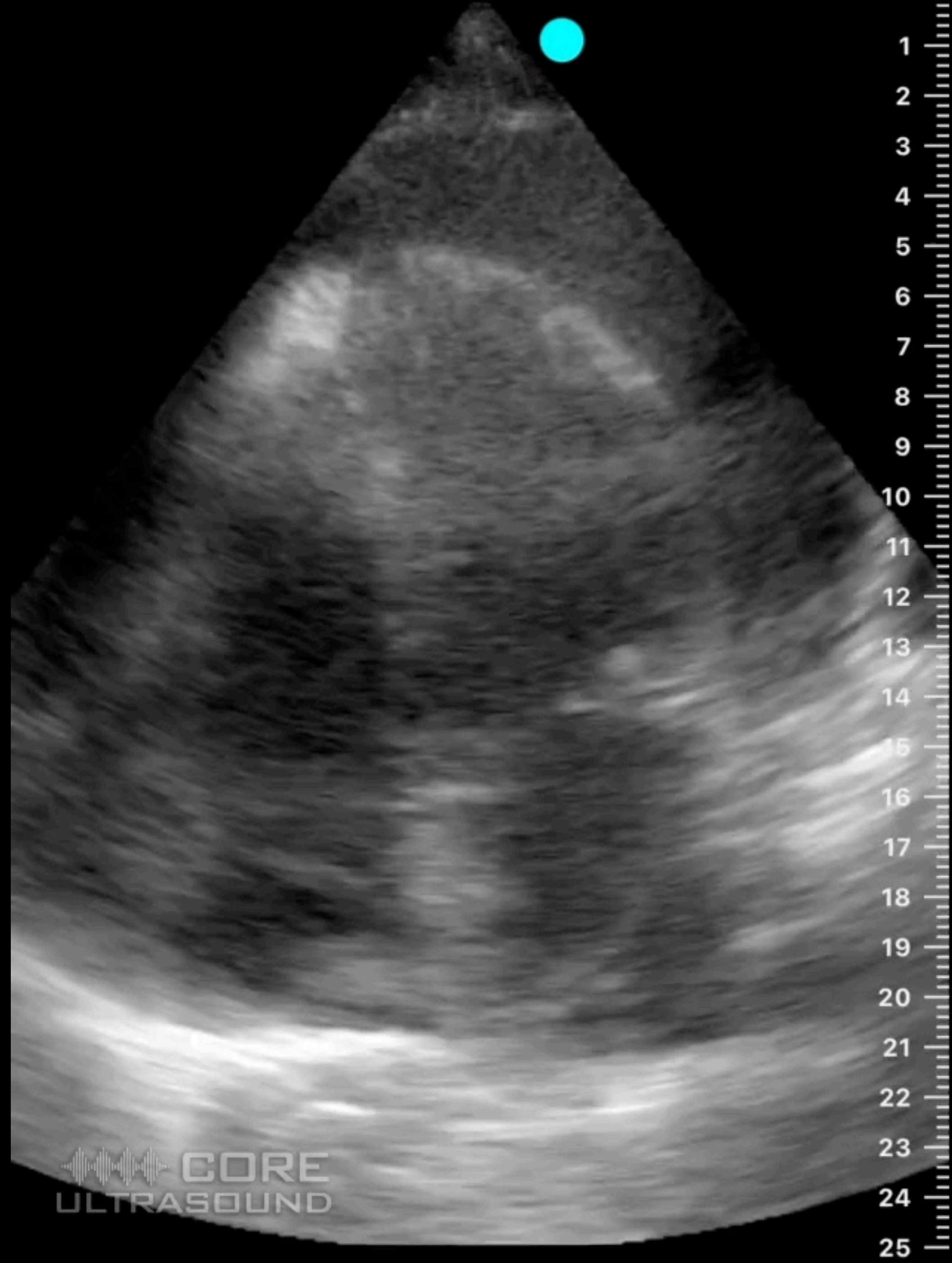
OBJECTIVES:

5 Cases + Pro tips

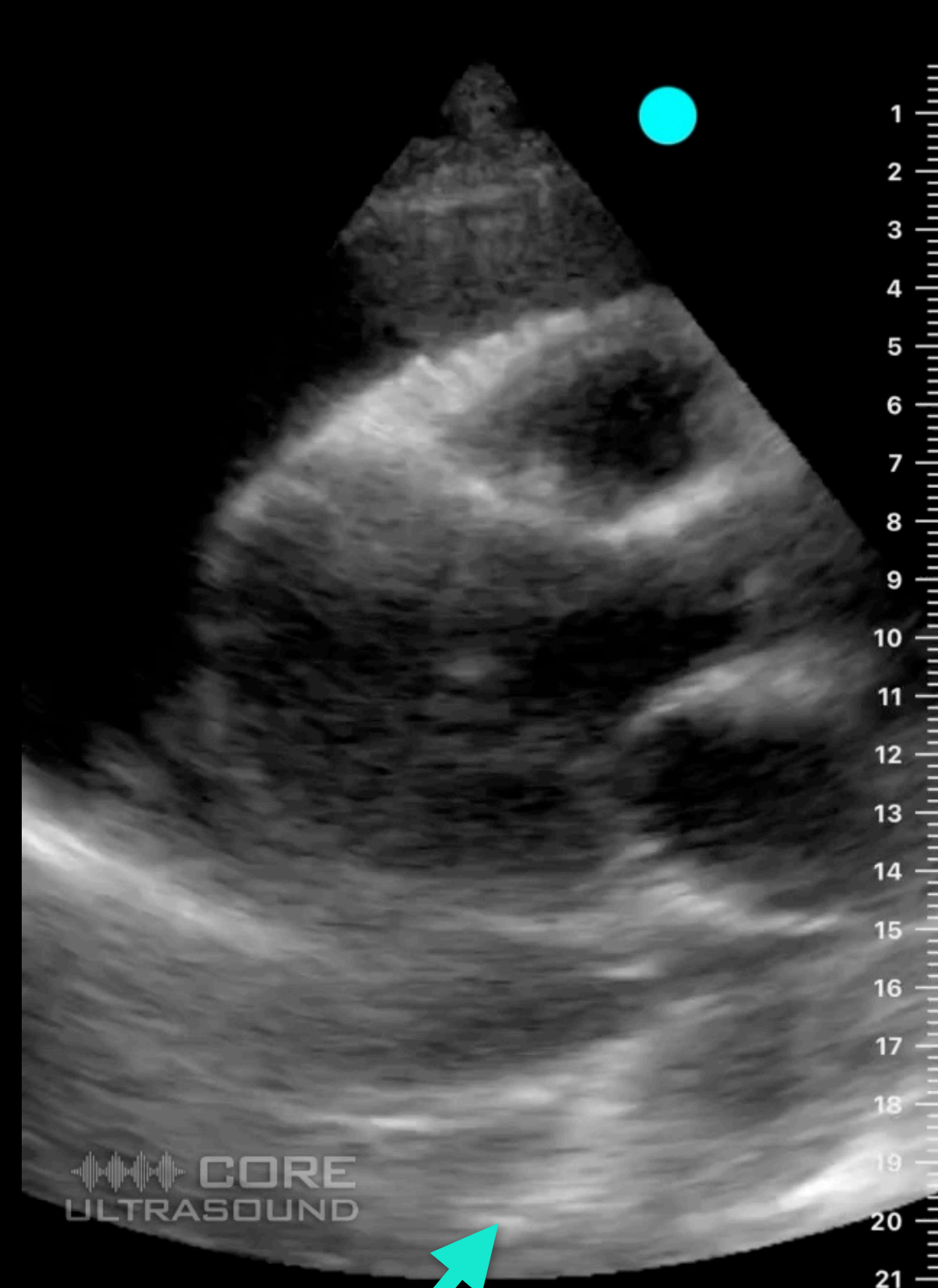
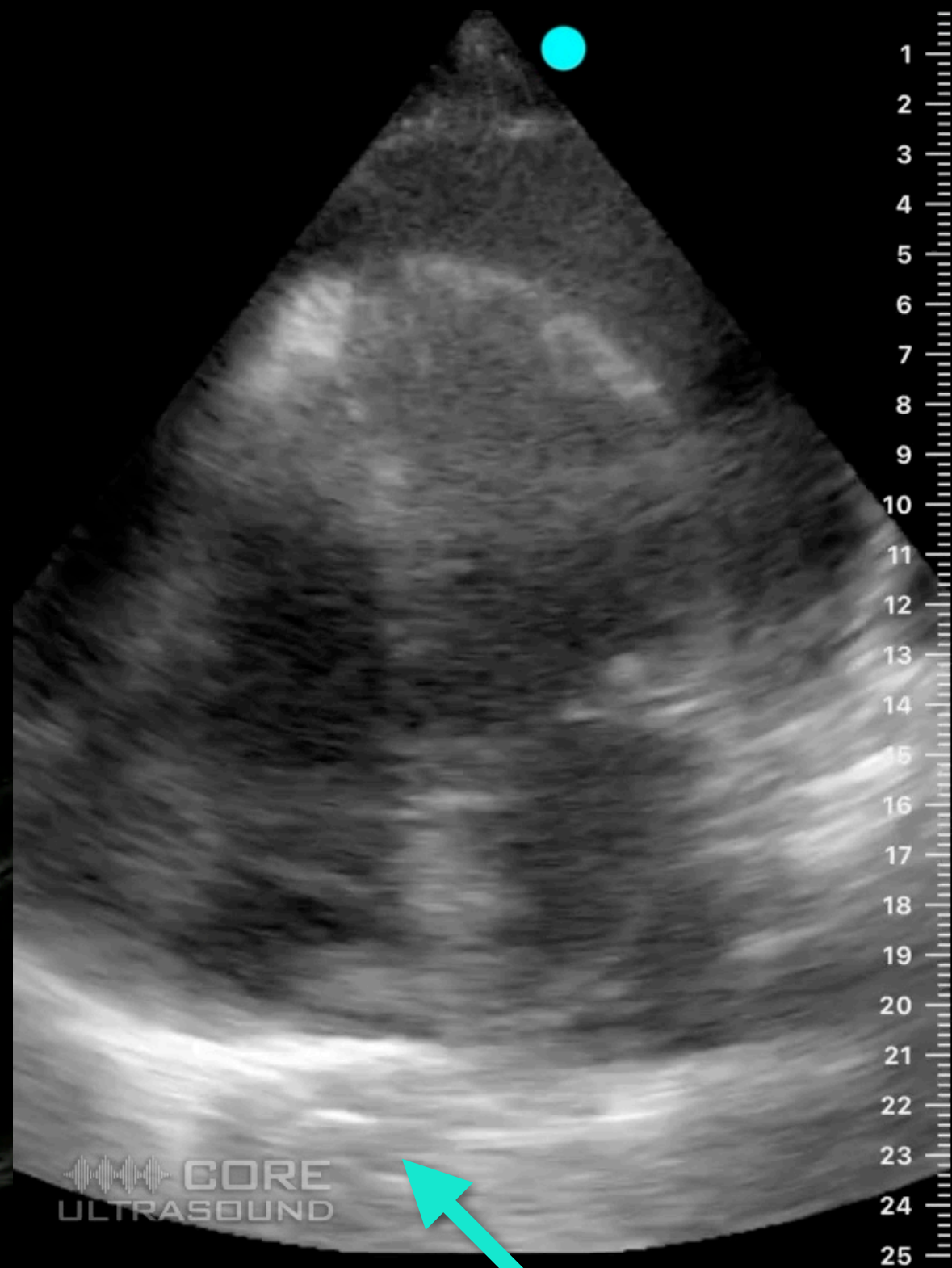
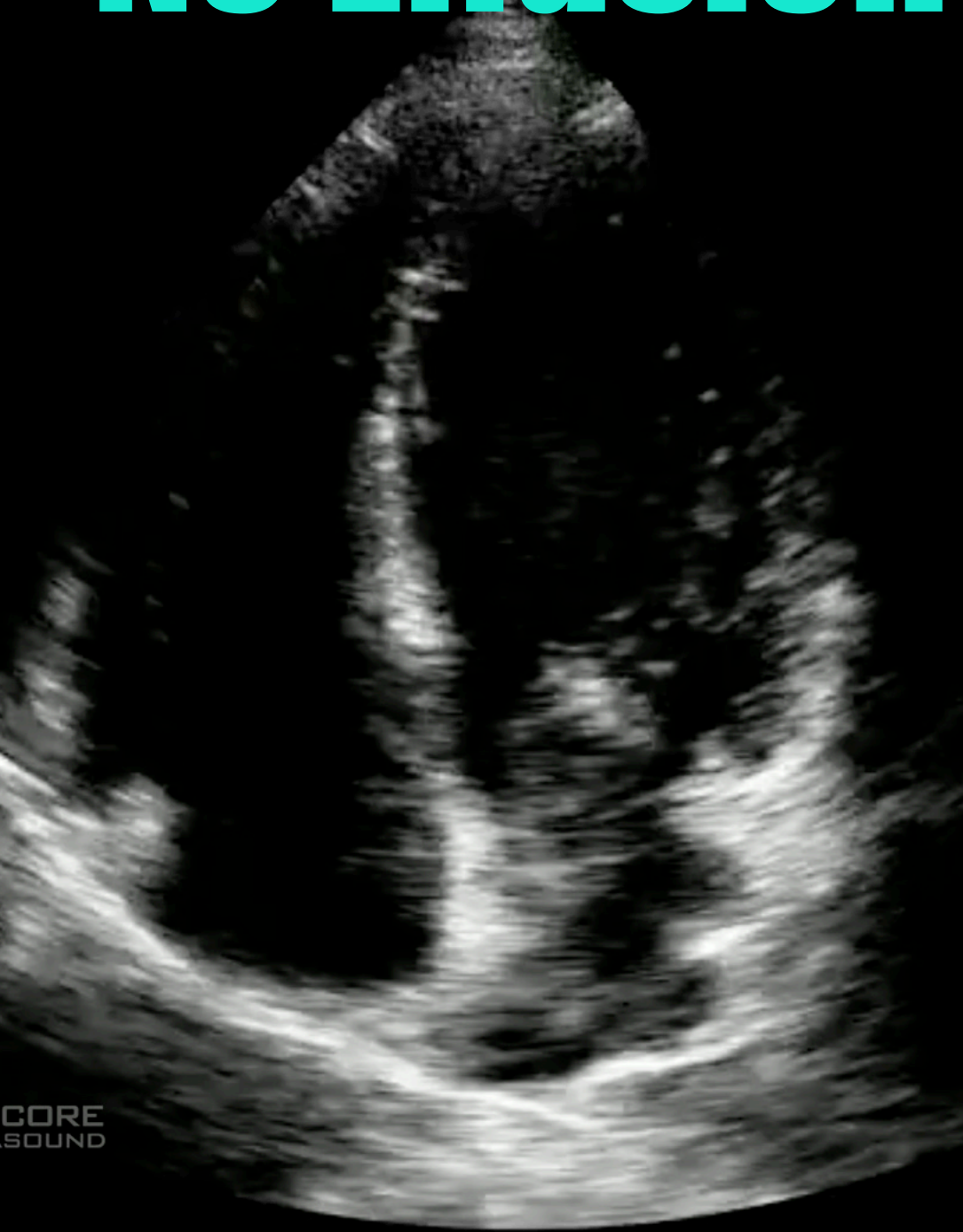65f

“STEMI”

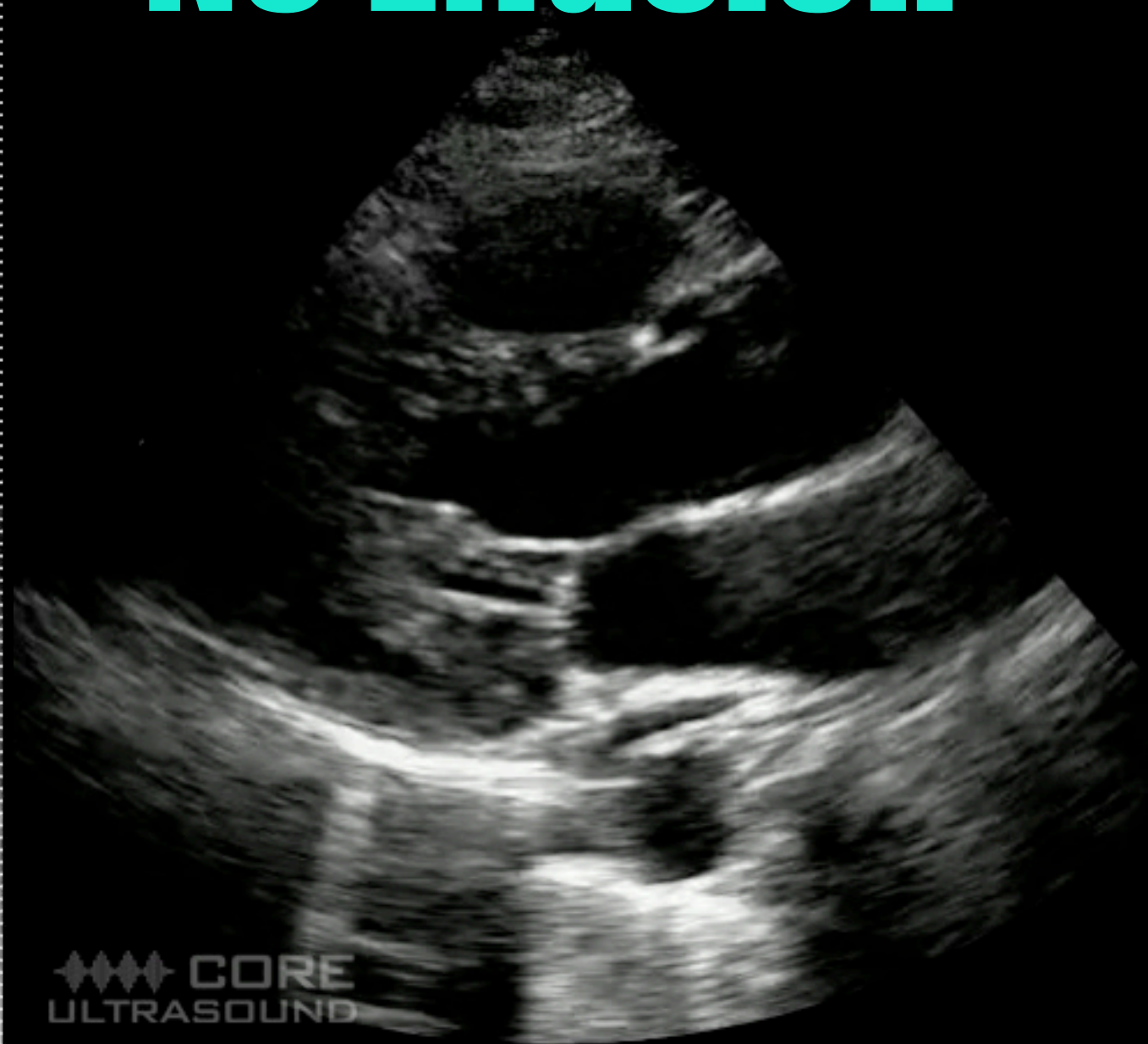





No Effusion



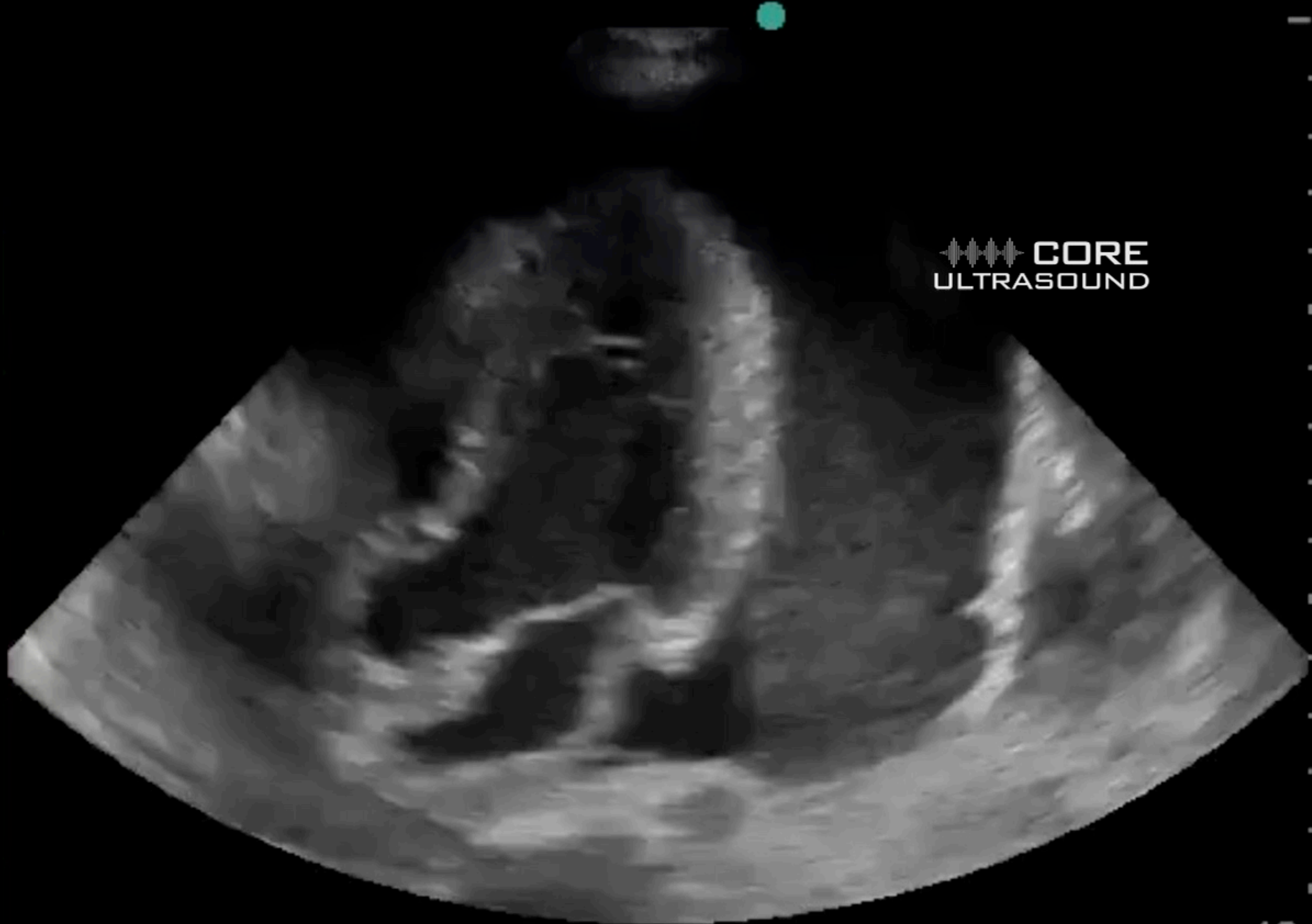No Effusion



Effusion



Effusion vs tamponade?



 **CORE**
ULTRASOUND

Tamponade =

Pericardial effusion

+

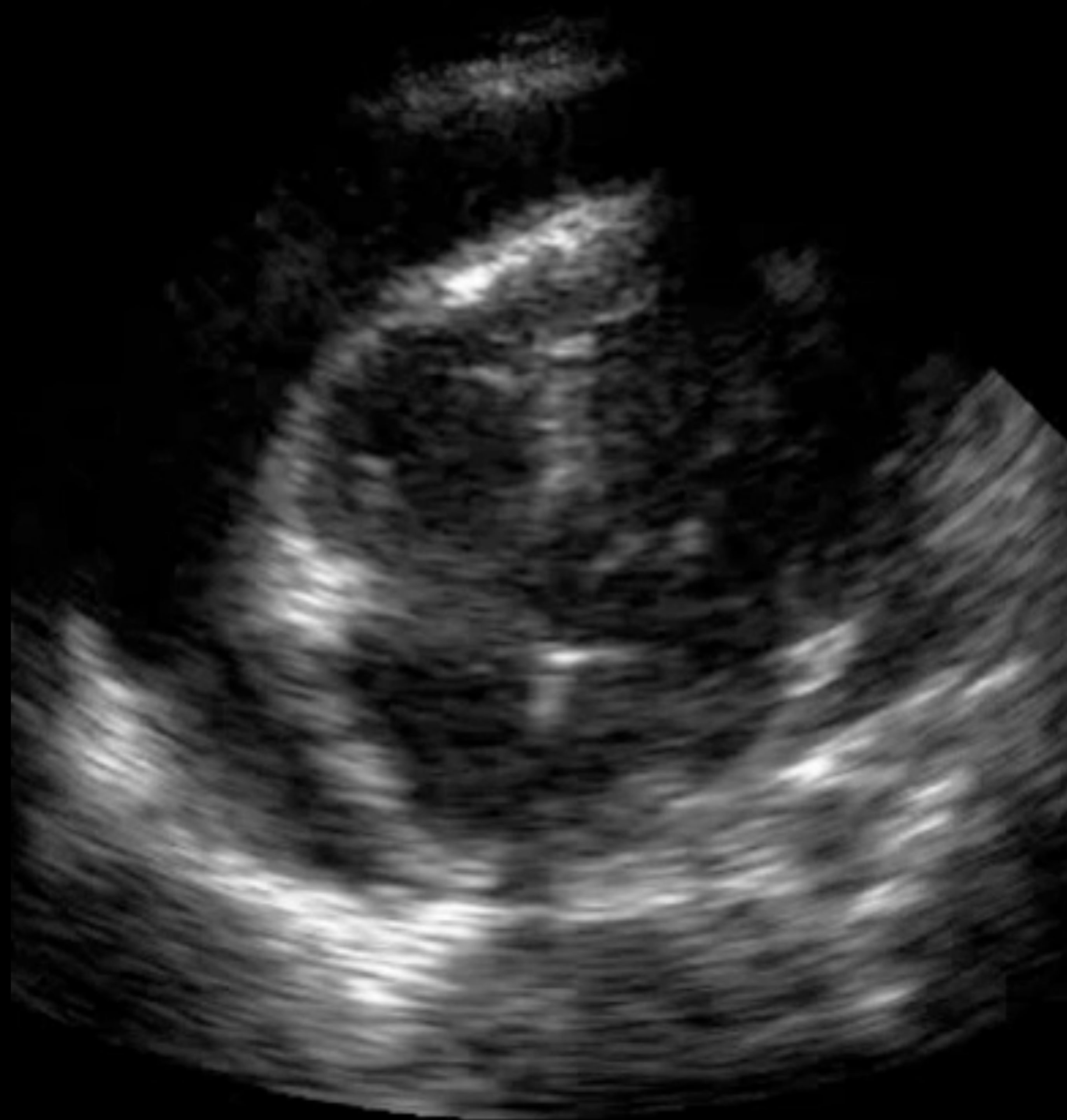RA diastolic collapse

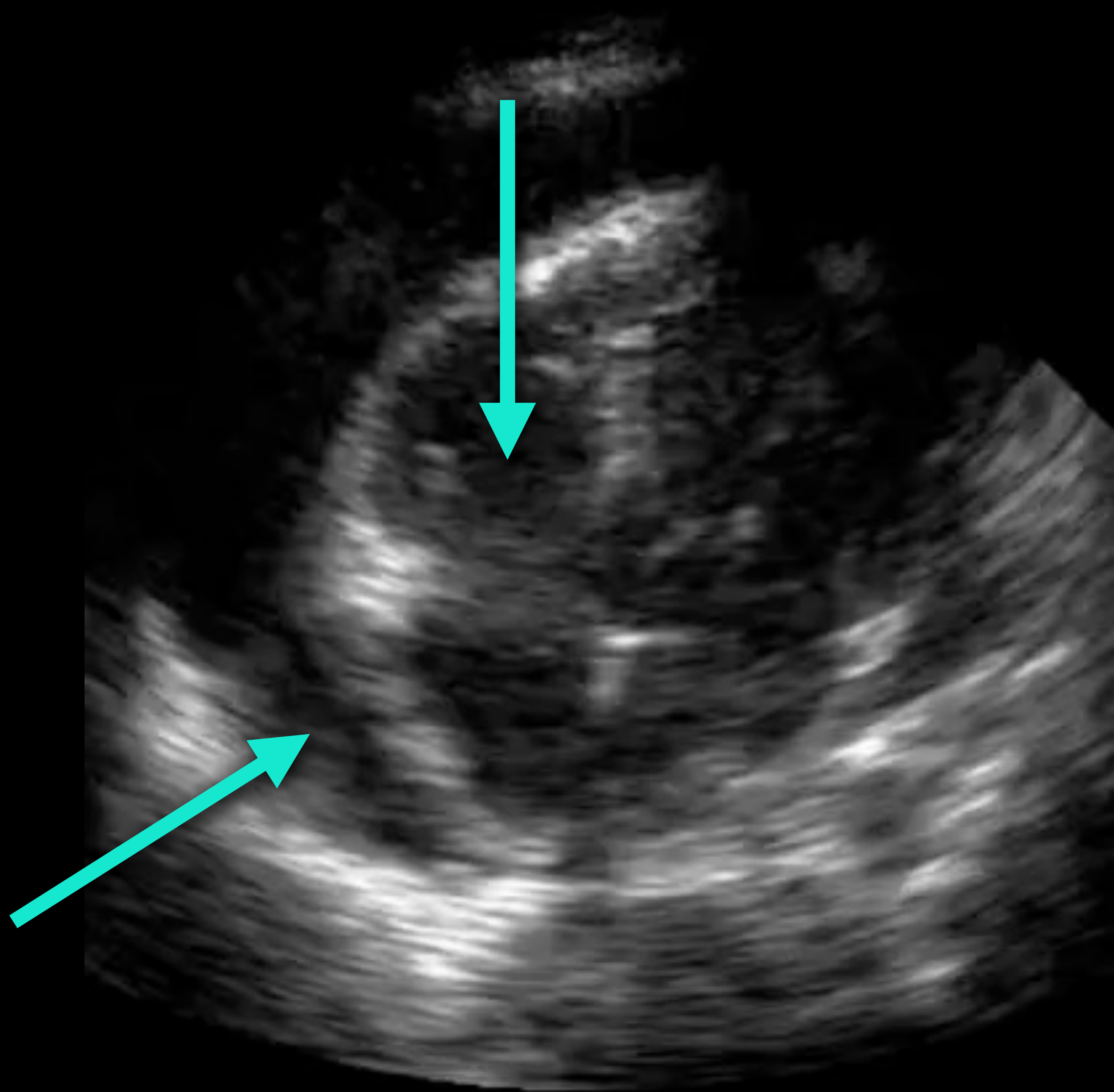
RV diastolic collapse

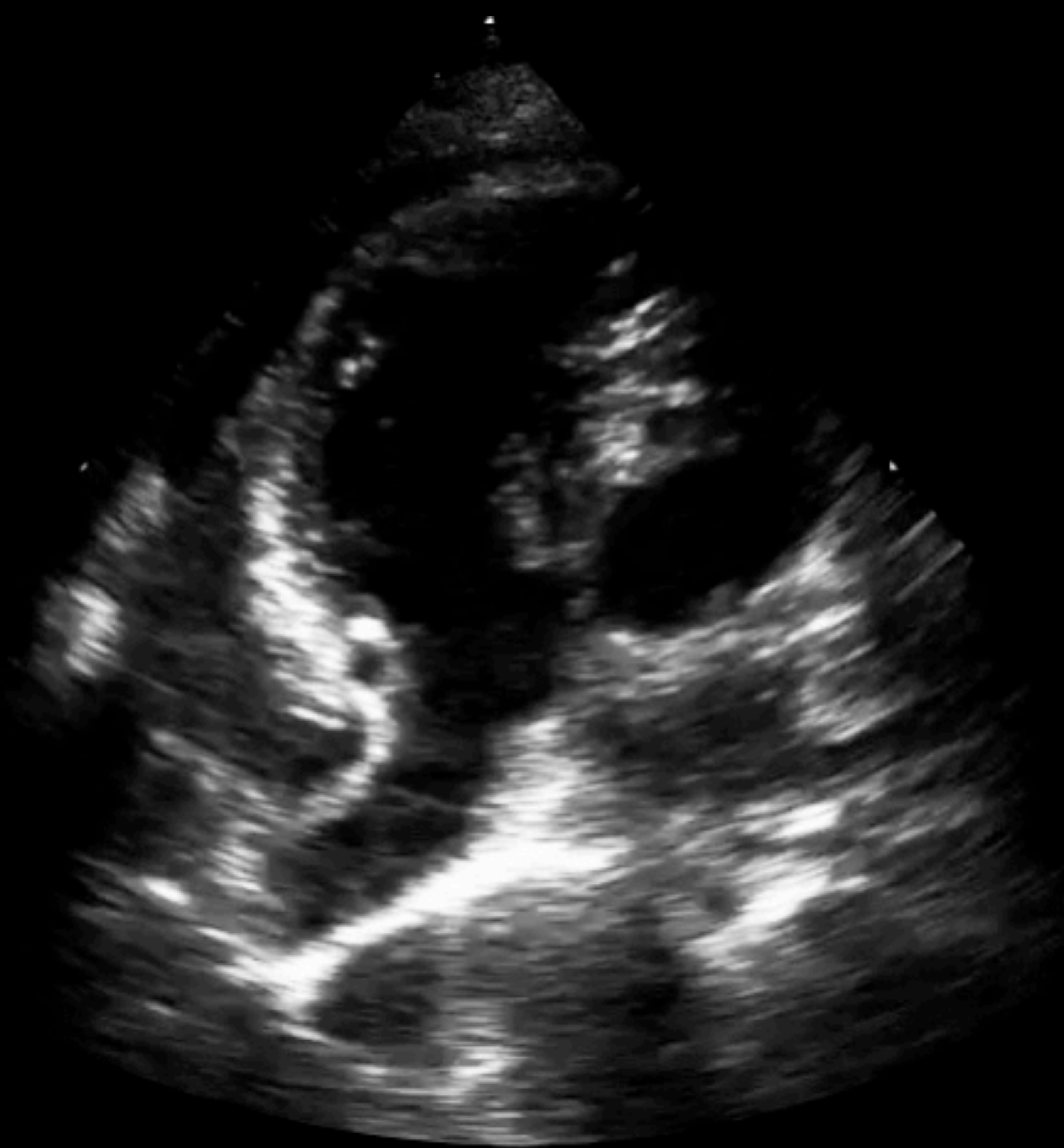Pulsus paradoxus

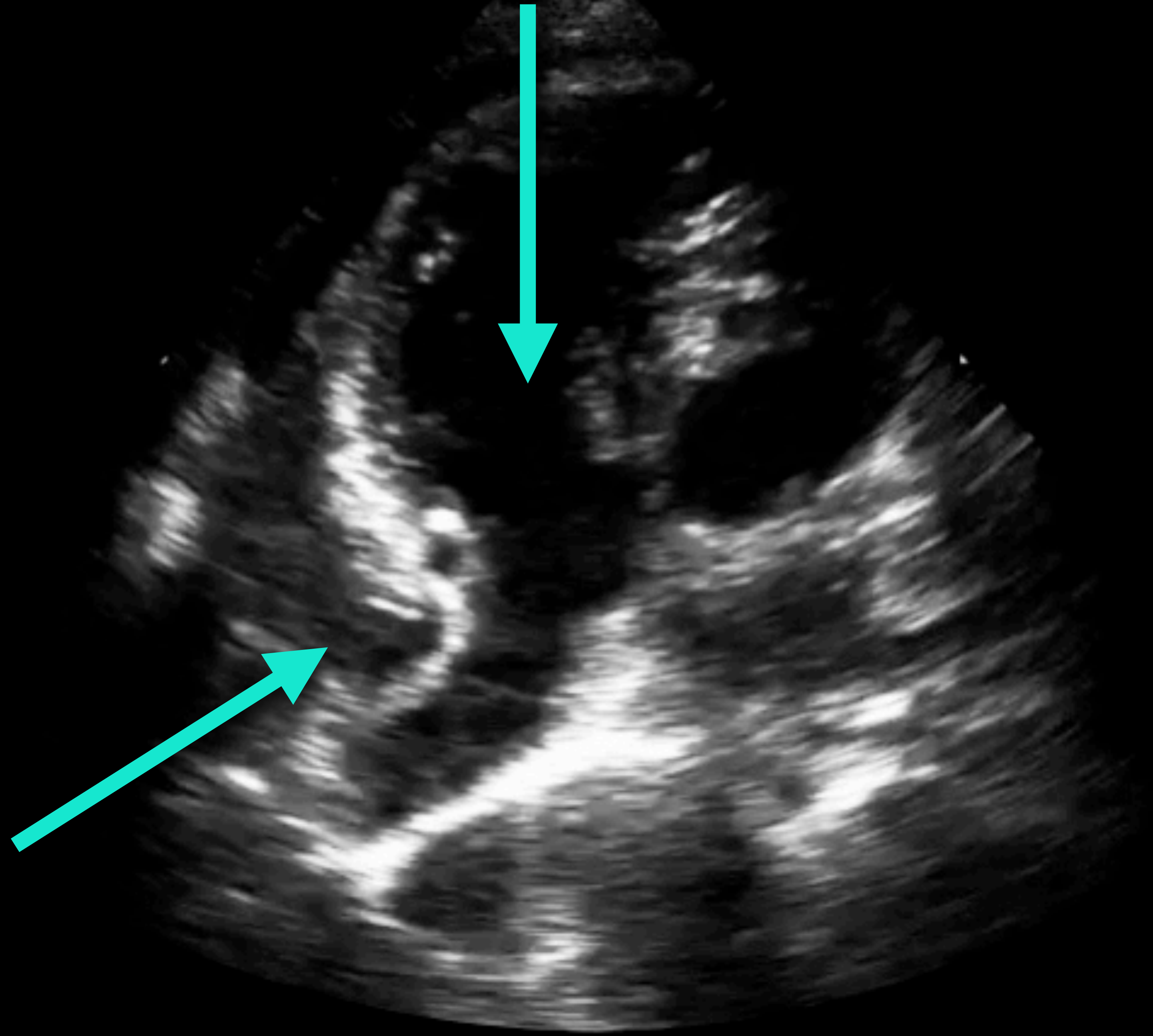
±

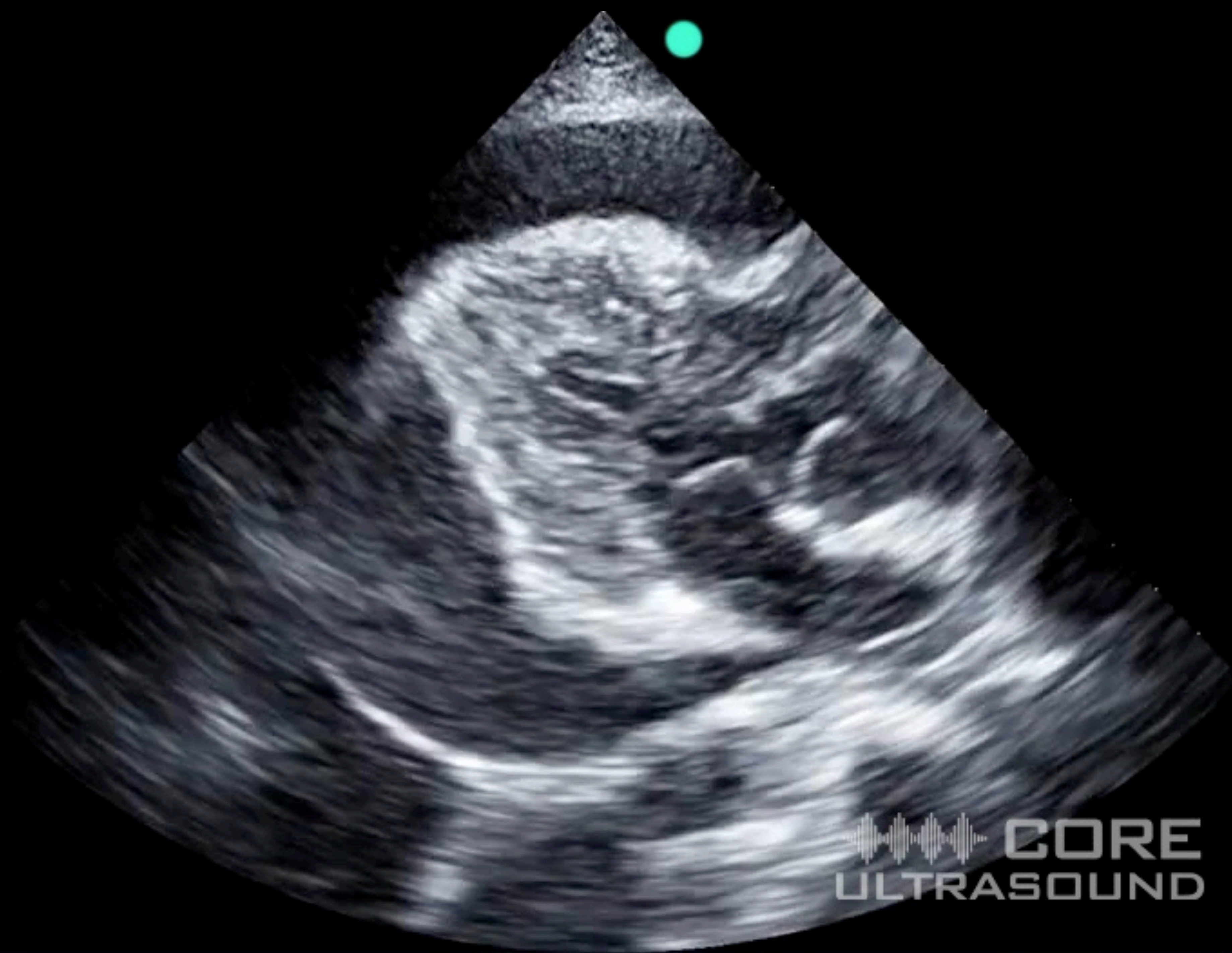
Dilated IVC



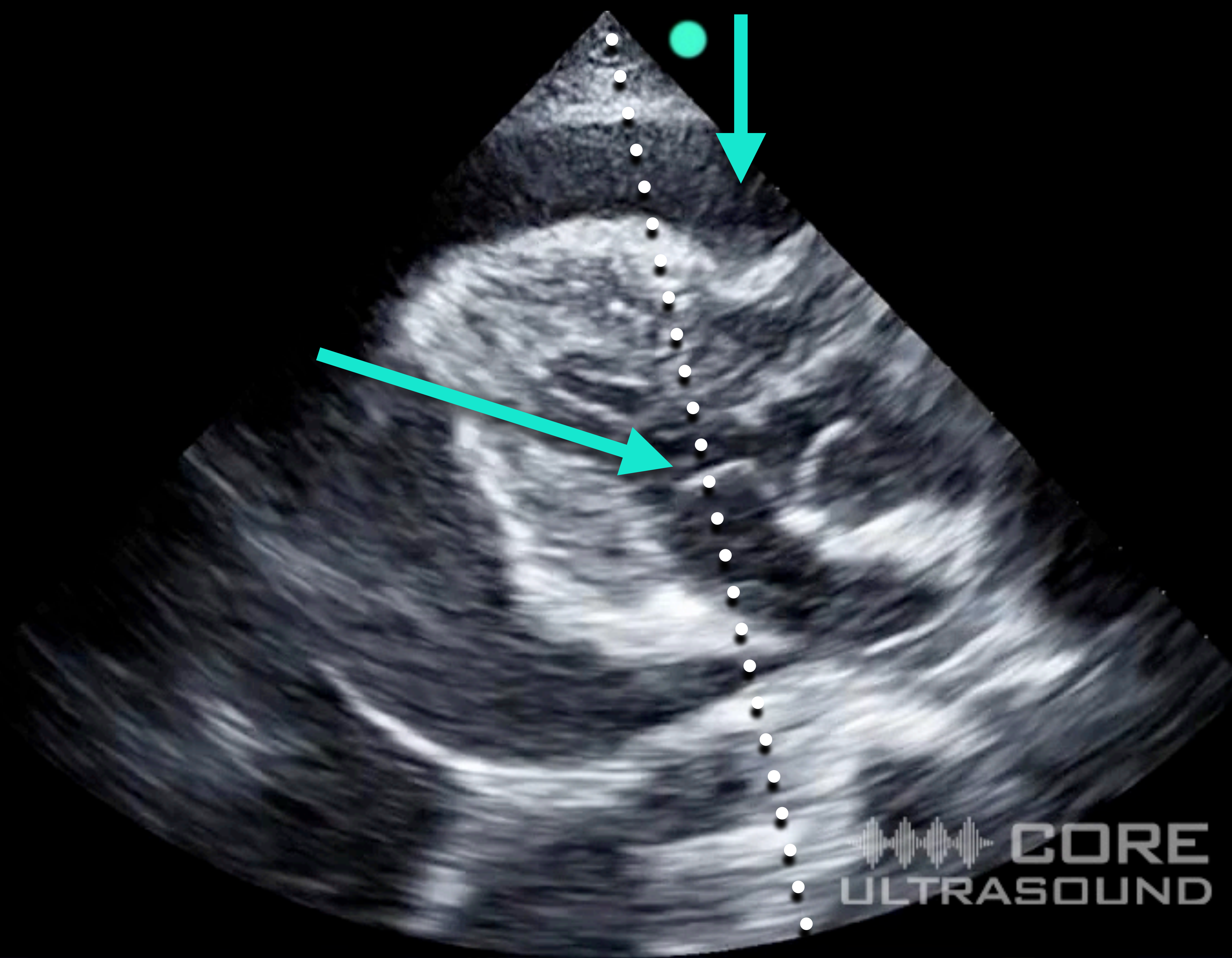




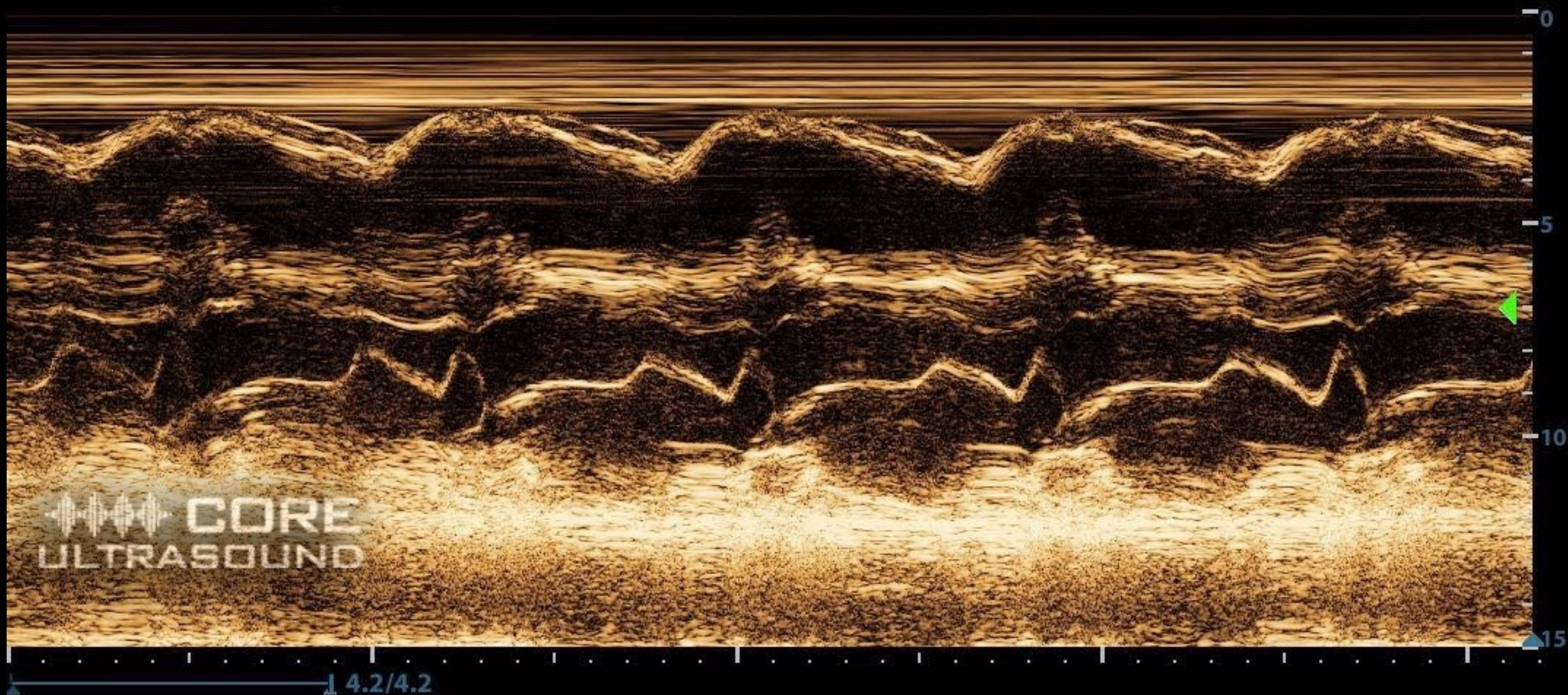
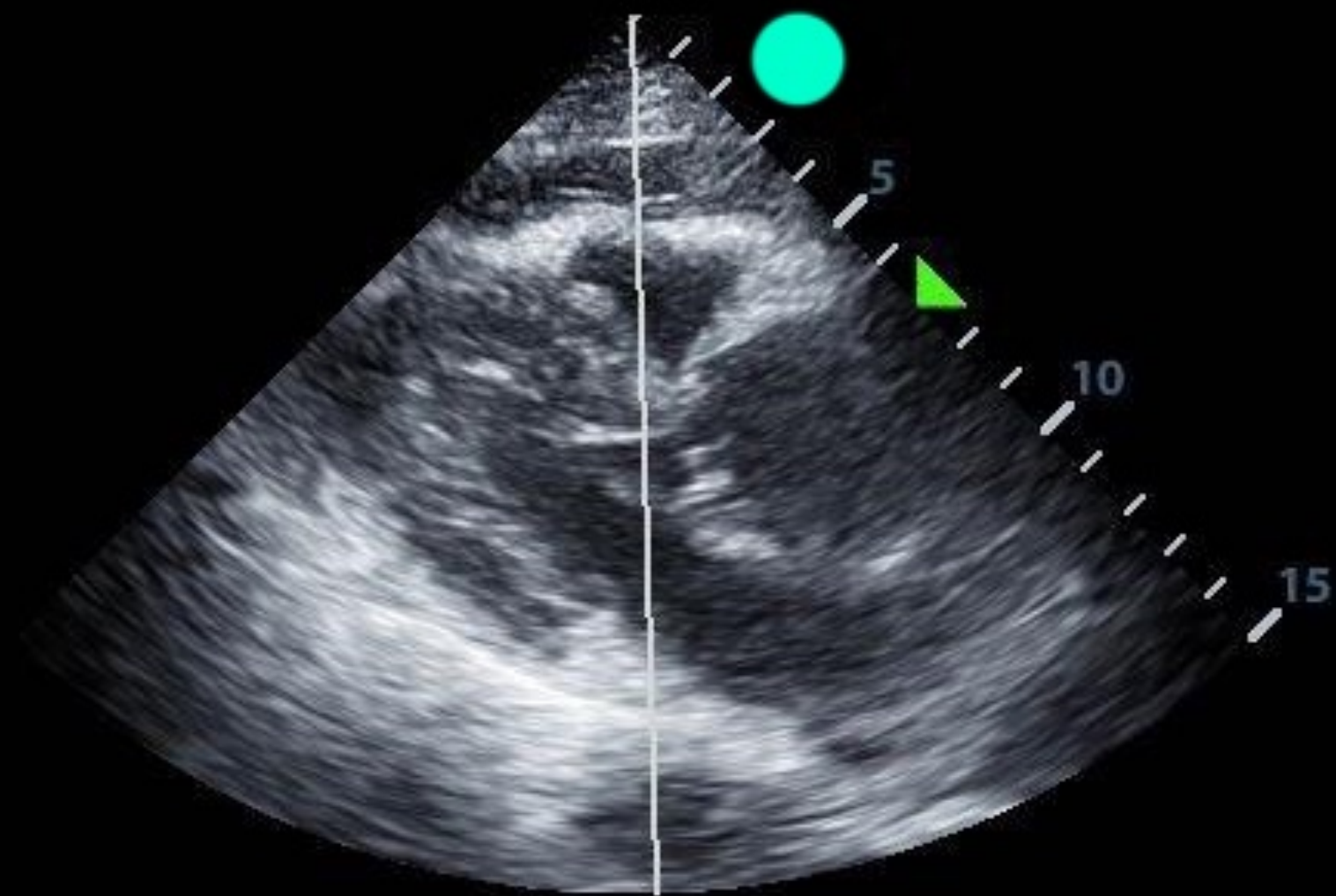


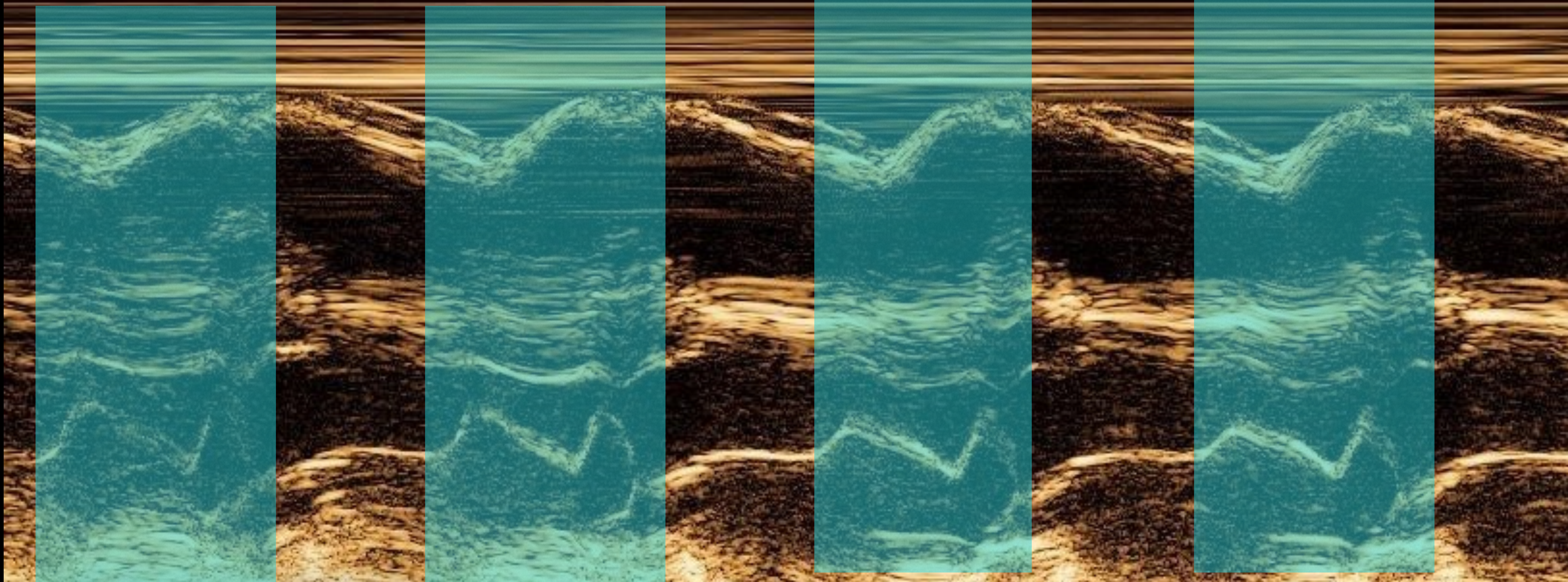


 **CORE**
ULTRASOUND



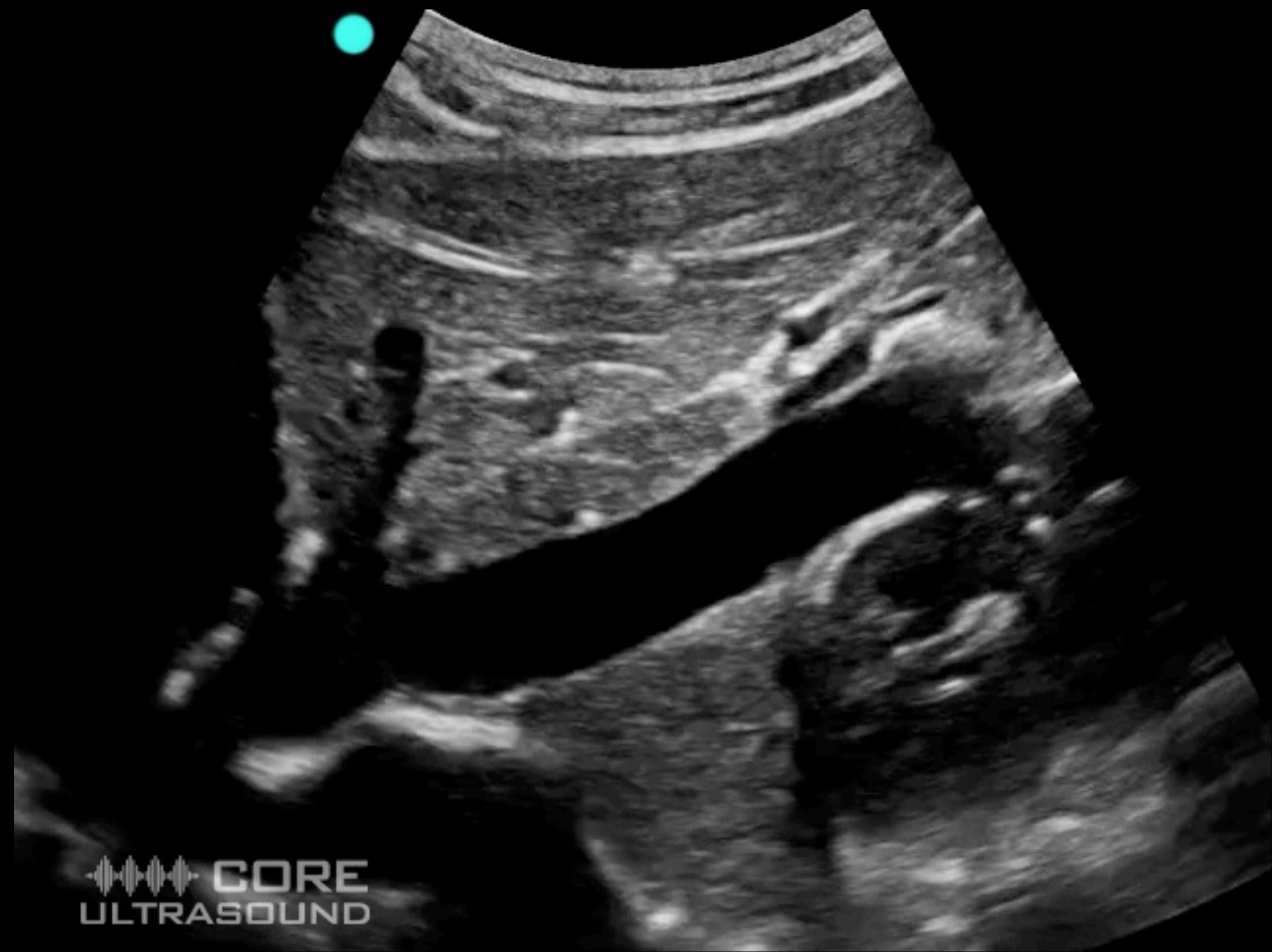CORE
ULTRASOUND



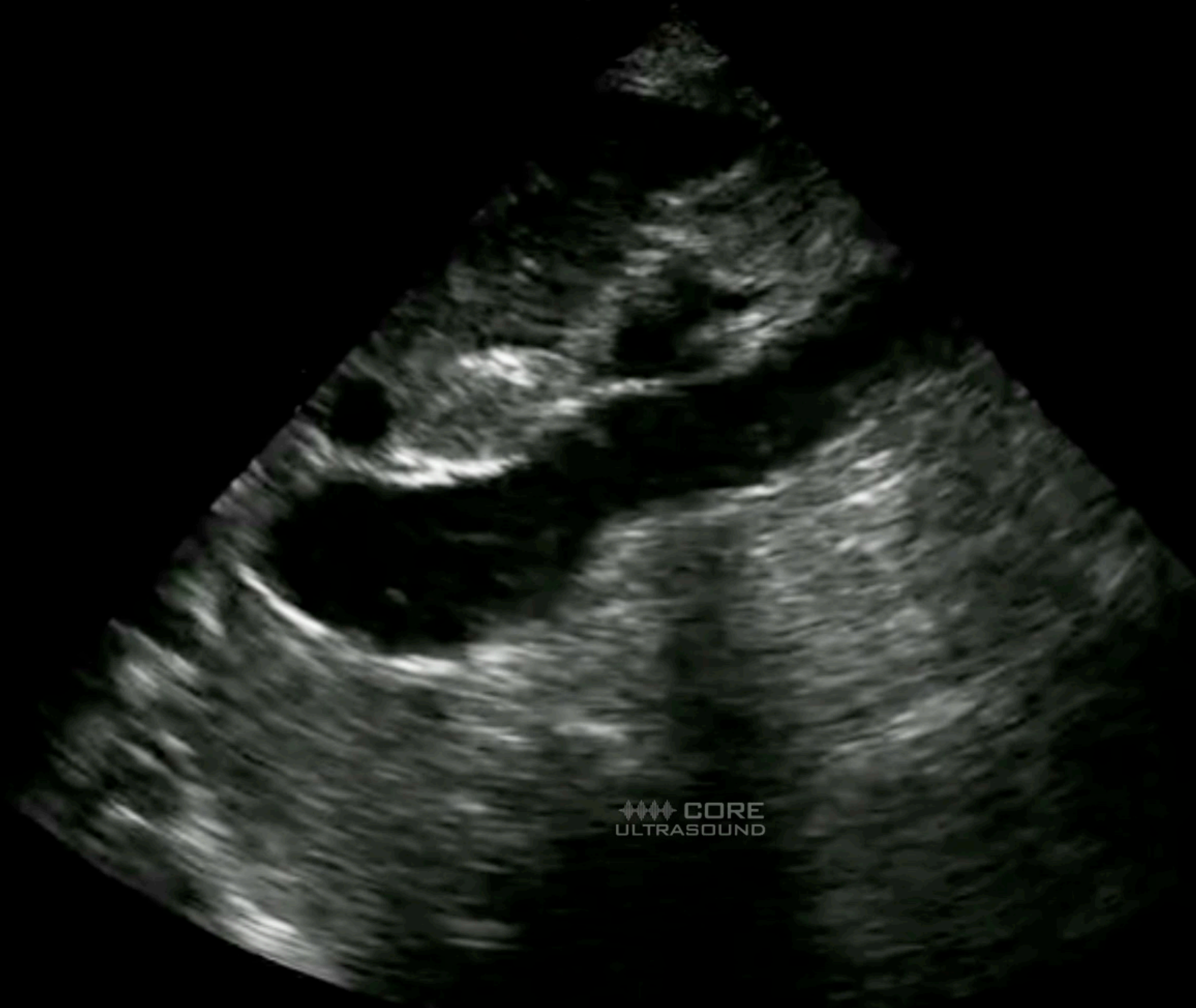

 CORE
ULTRASOUND

4.2/4.2



 CORE
ULTRASOUND

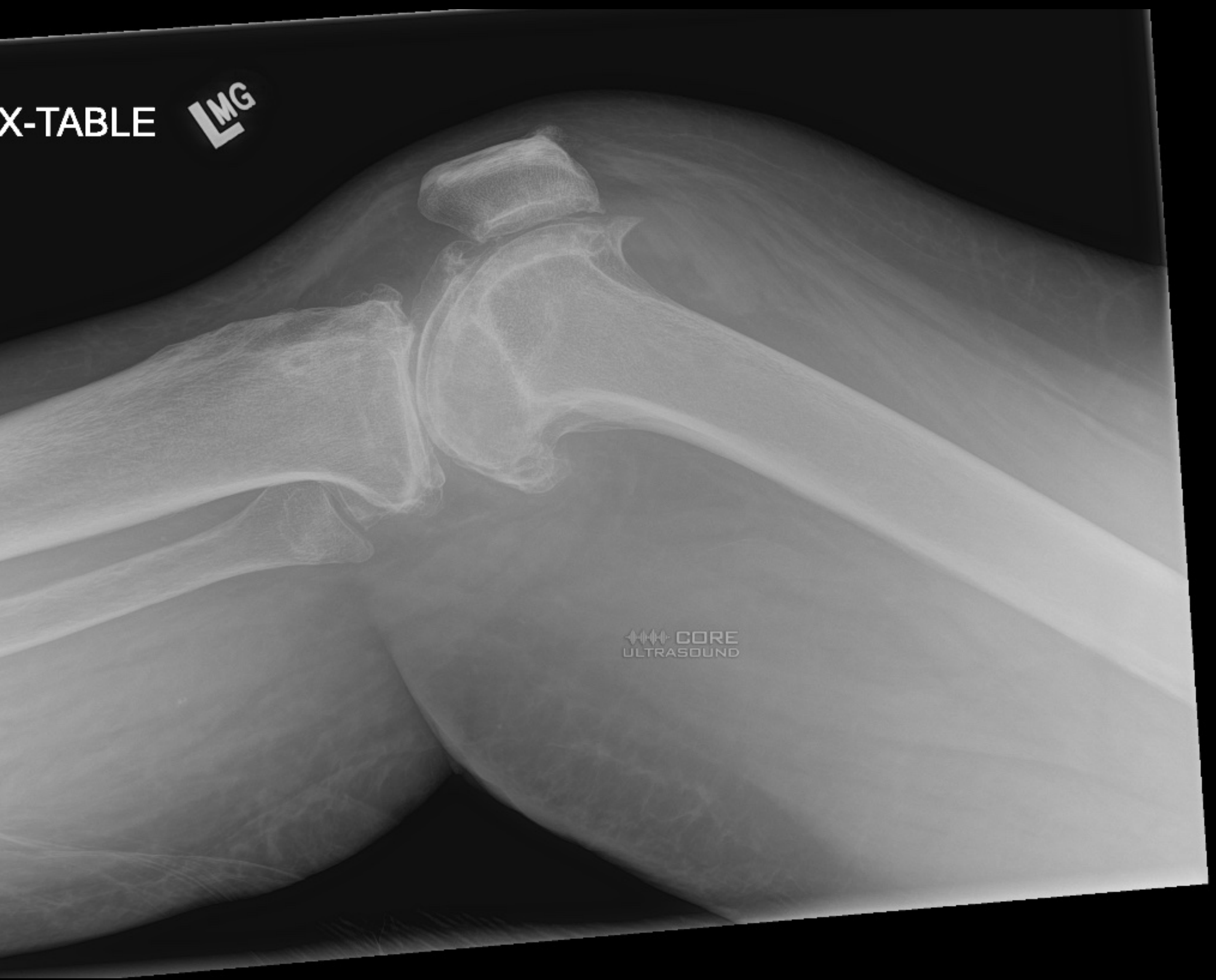

 CORE
ULTRASOUND

62f

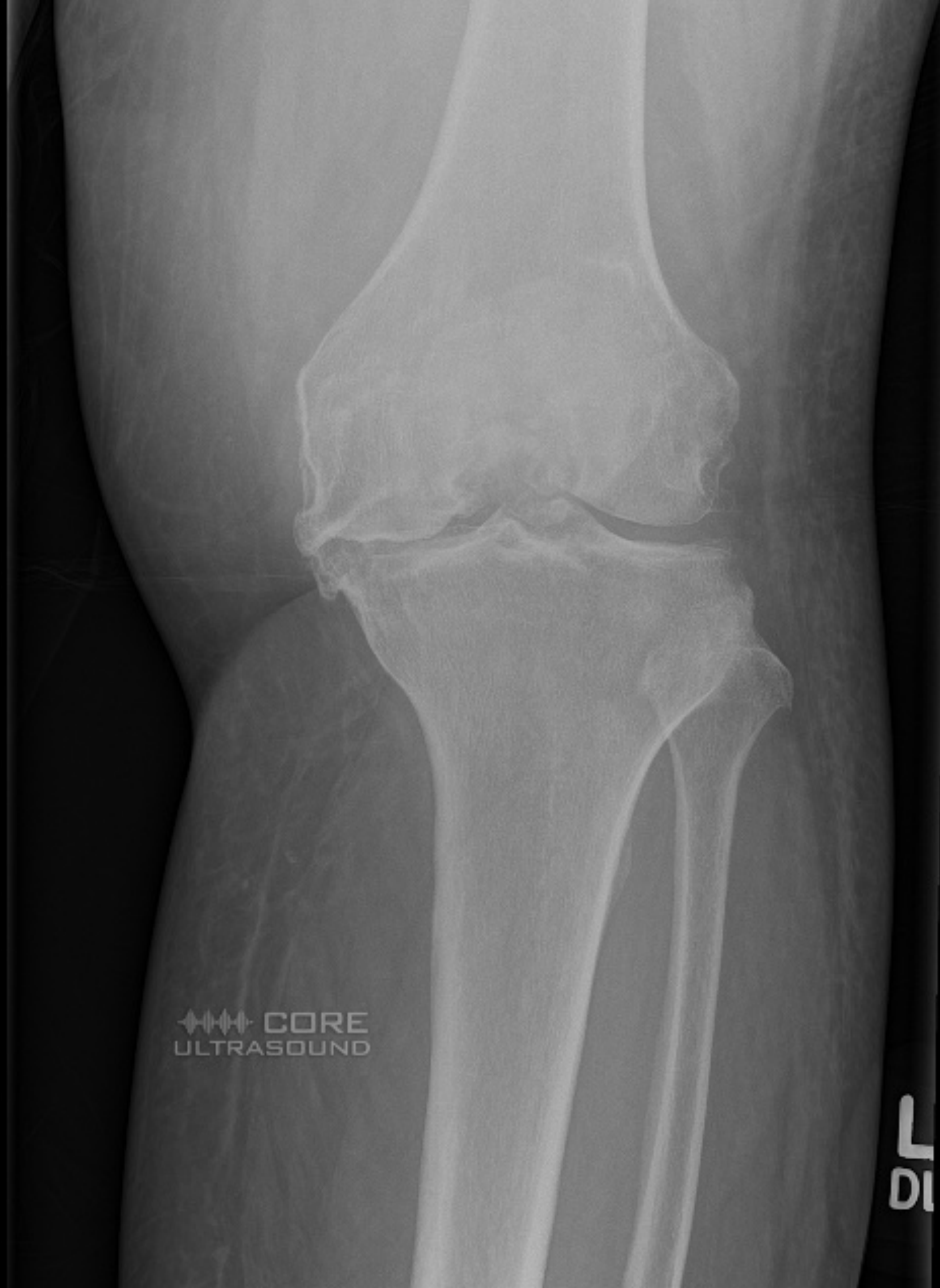“Knee pain”

X-TABLE LMG

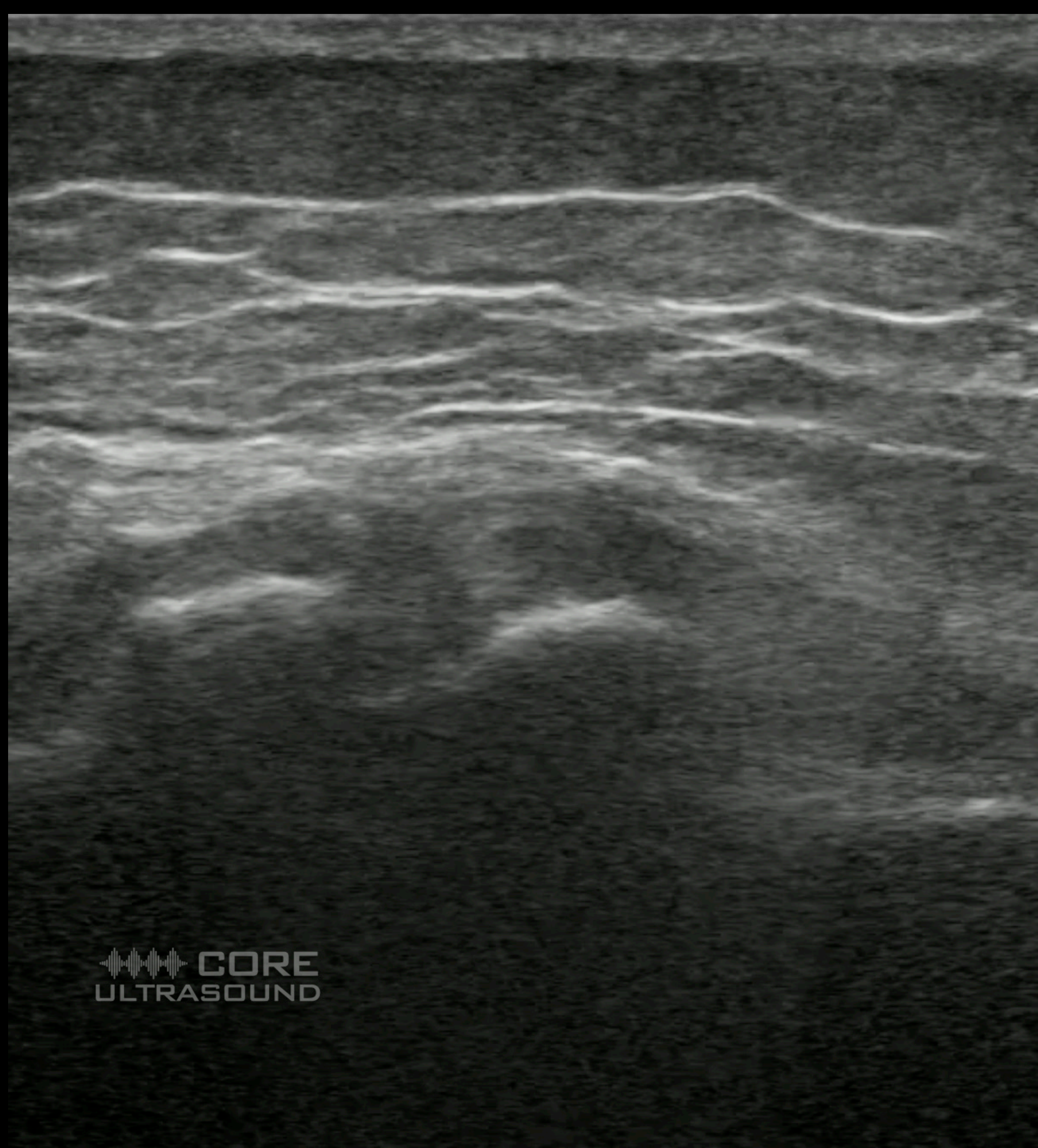


CORE
ULTRASOUND

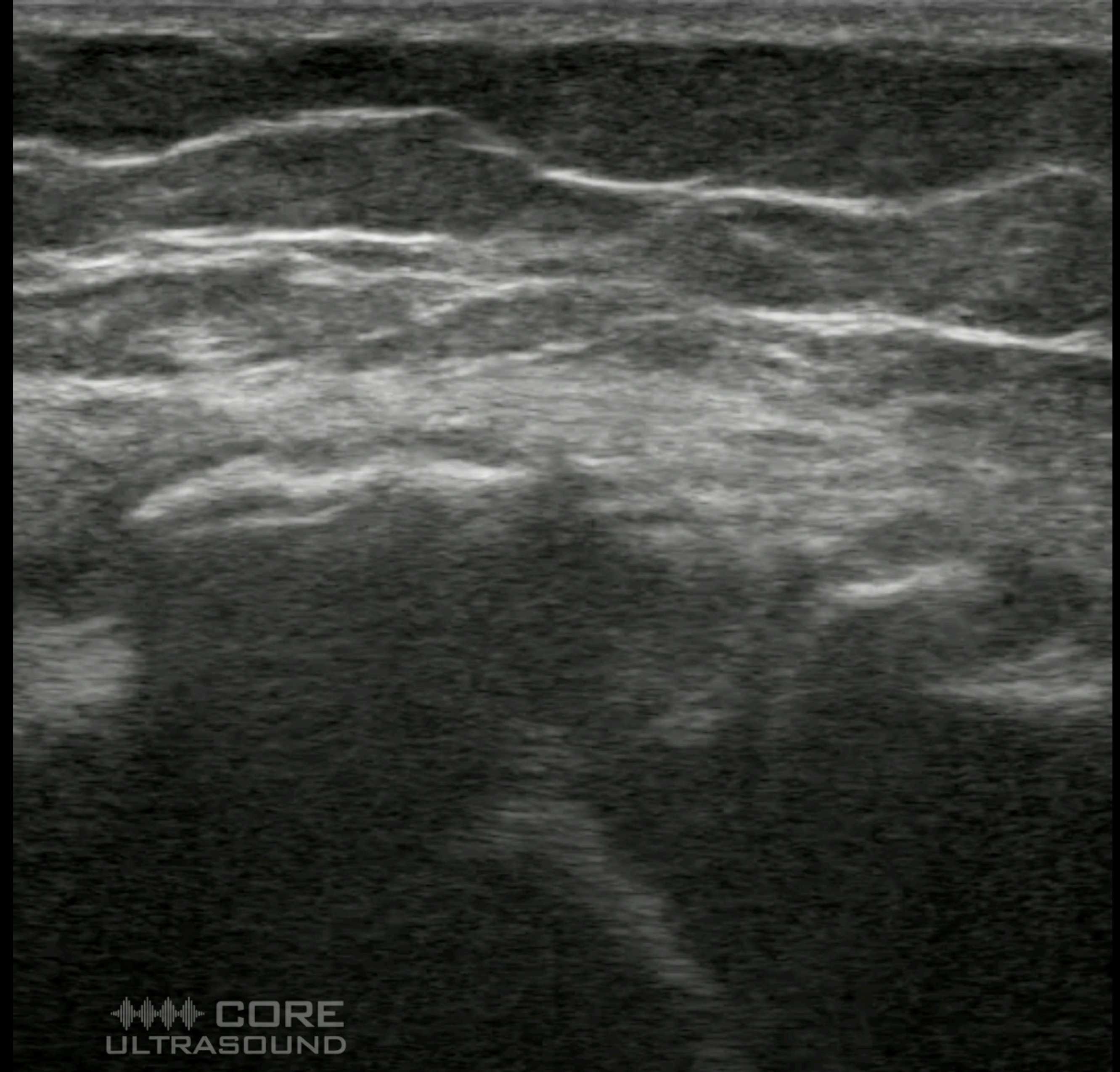
CORE
ULTRASOUND



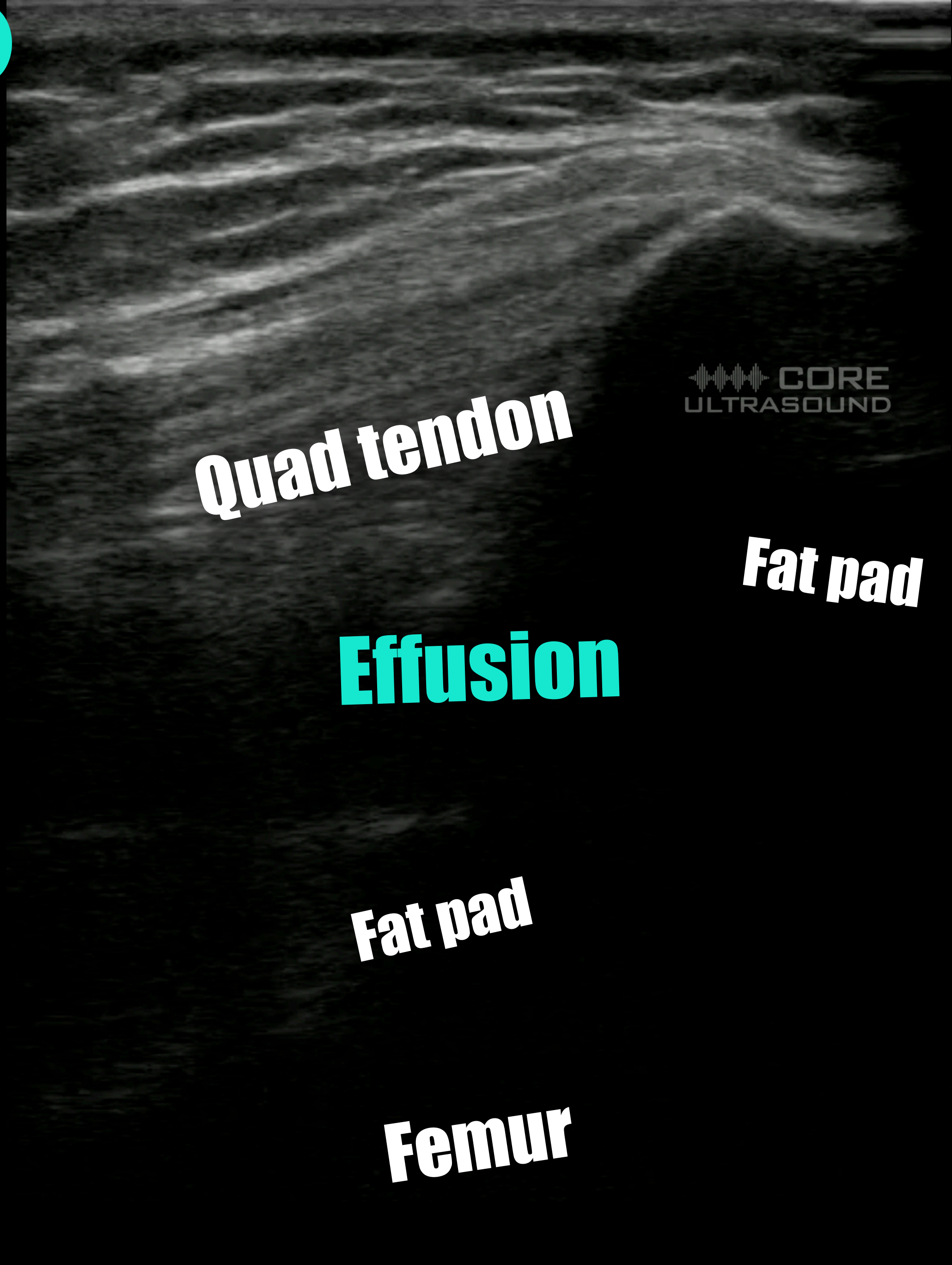
L
DI



 **CORE**
ULTRASOUND



 **CORE**
ULTRASOUND



Quad tendon

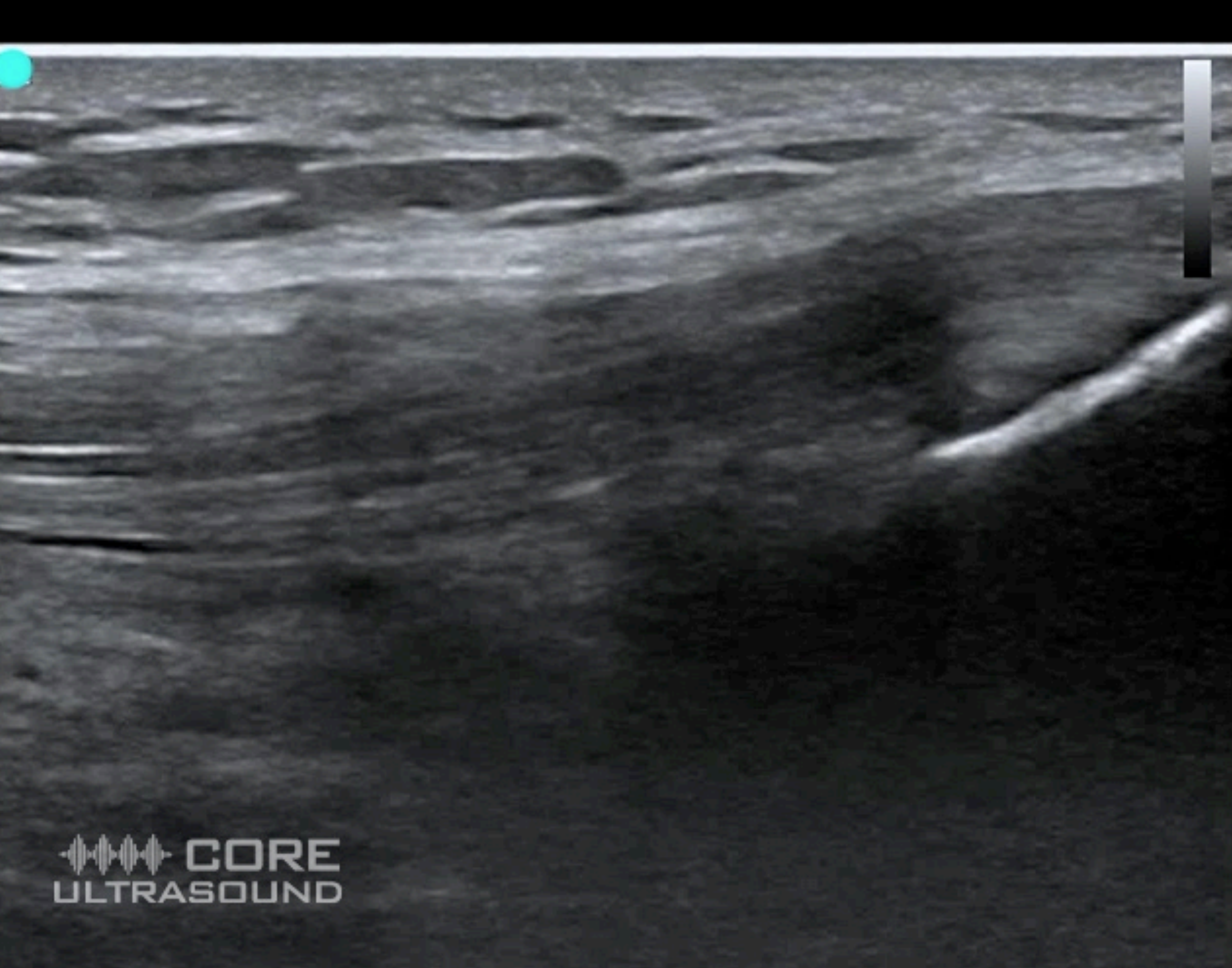
CORE
ULTRASOUND

Fat pad

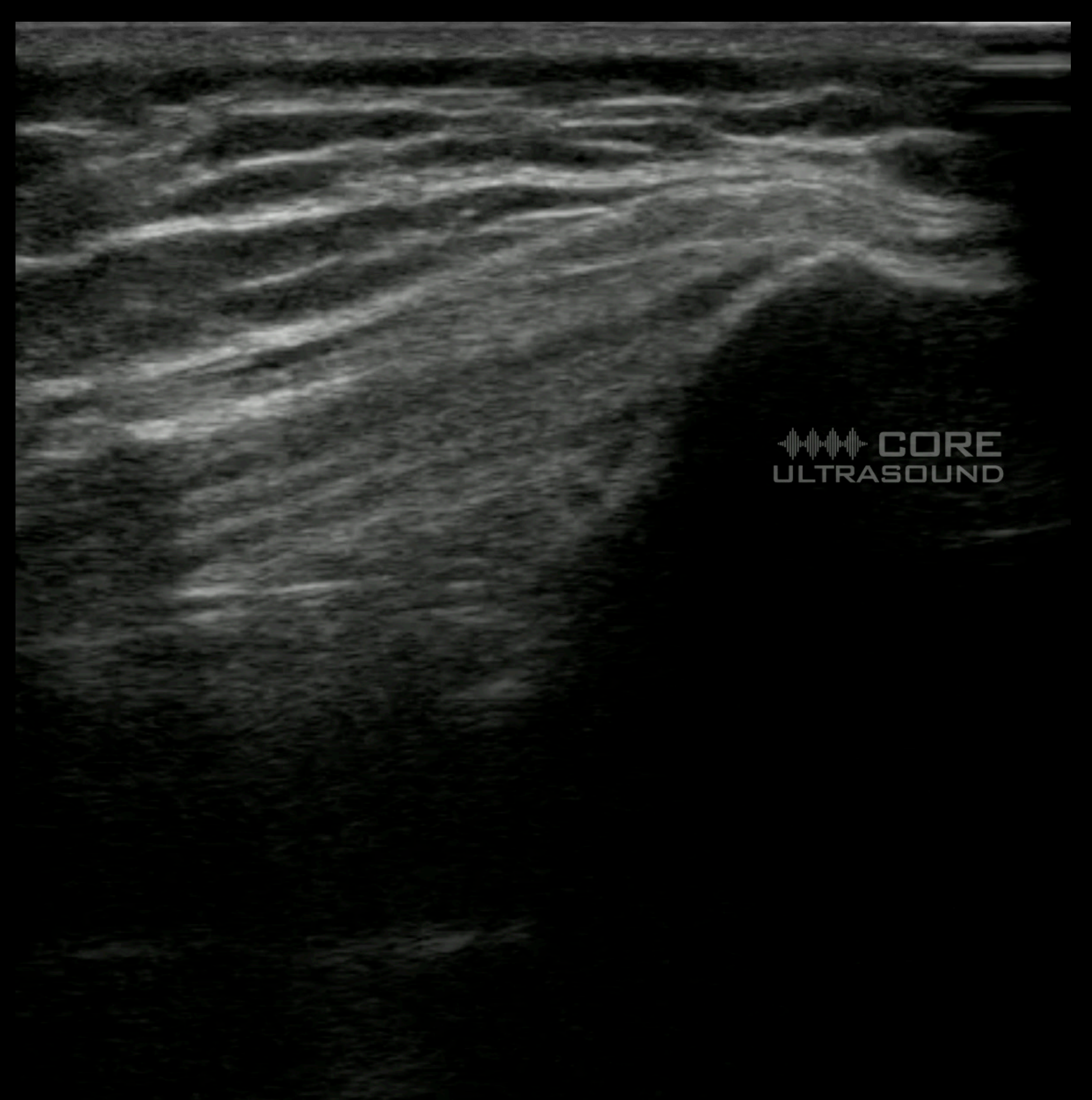Effusion

Fat pad

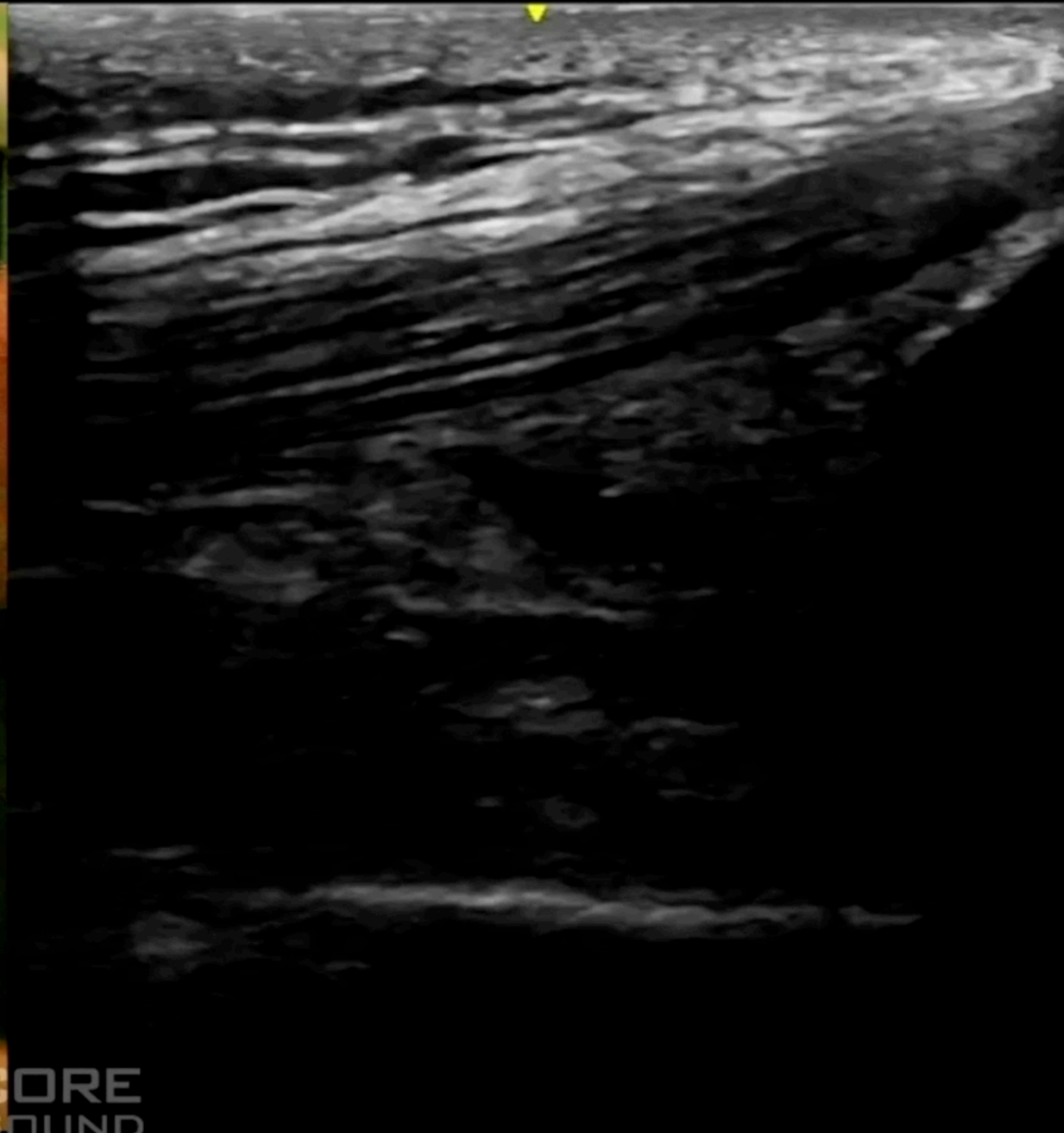
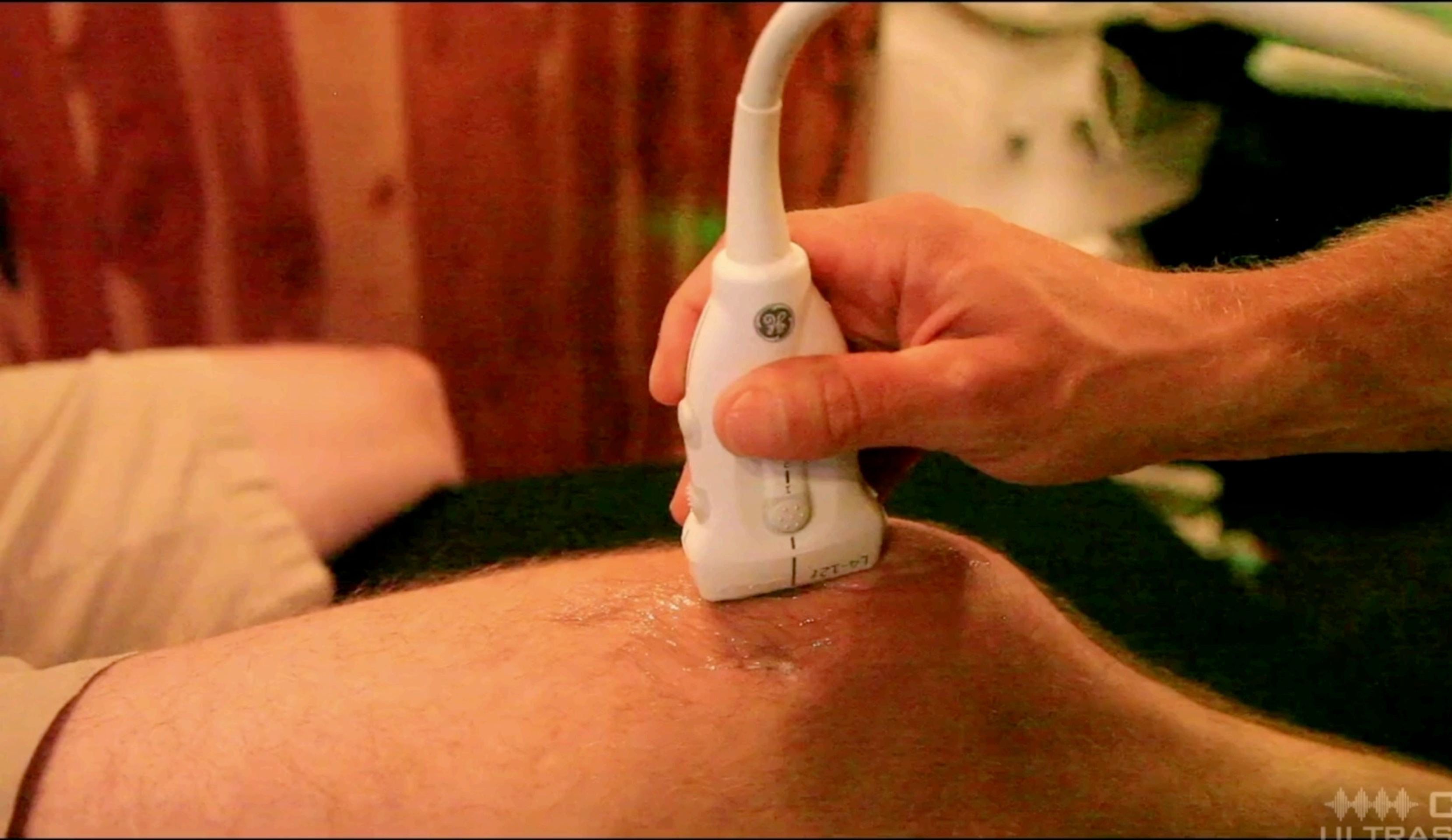Femur



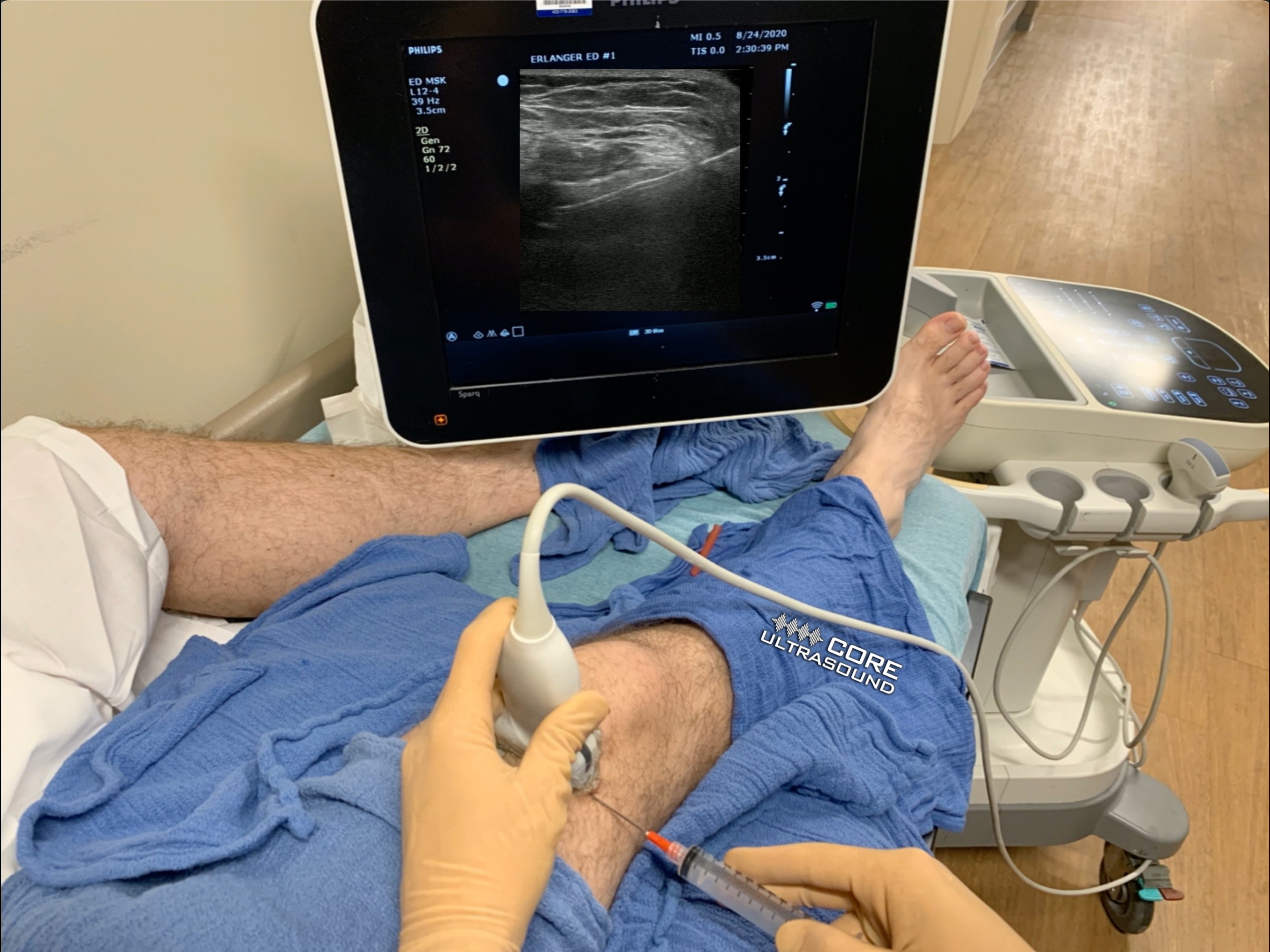 CORE
ULTRASOUND



 CORE
ULTRASOUND



 **CORE**
ULTRASOUND

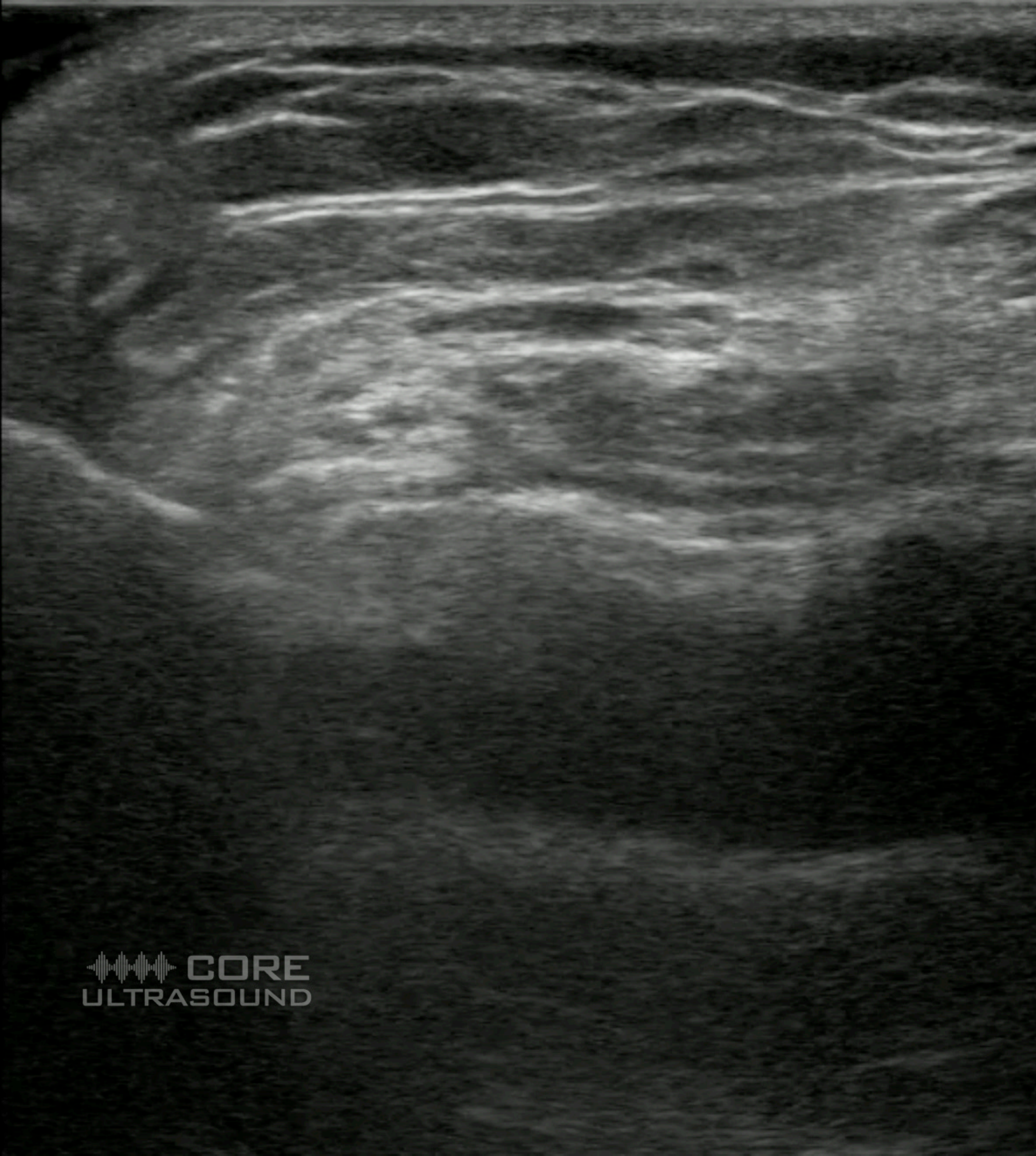


PHILIPS
ED MSK
L12-4
39 Hz
3.5cm
2D
Gen
Gn 72
60
1/2/2
Sparq

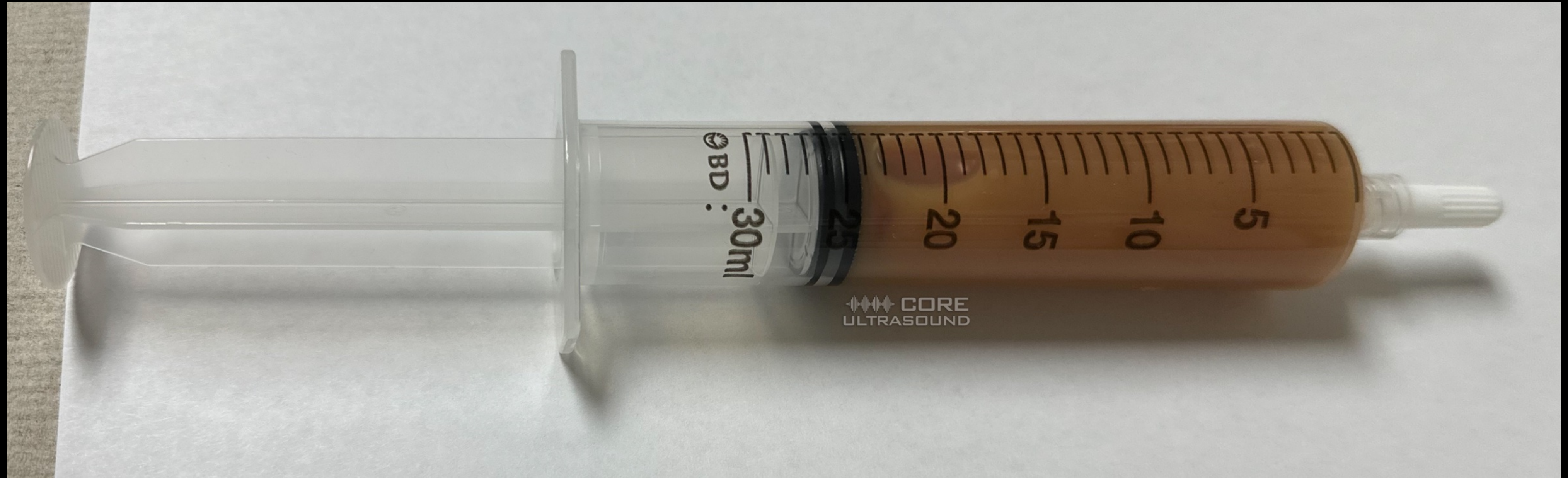
ERLANGER ED #1

MI 0.5 8/24/2020
TIS 0.0 2:30:39 PM

CORE
ULTRASOUND

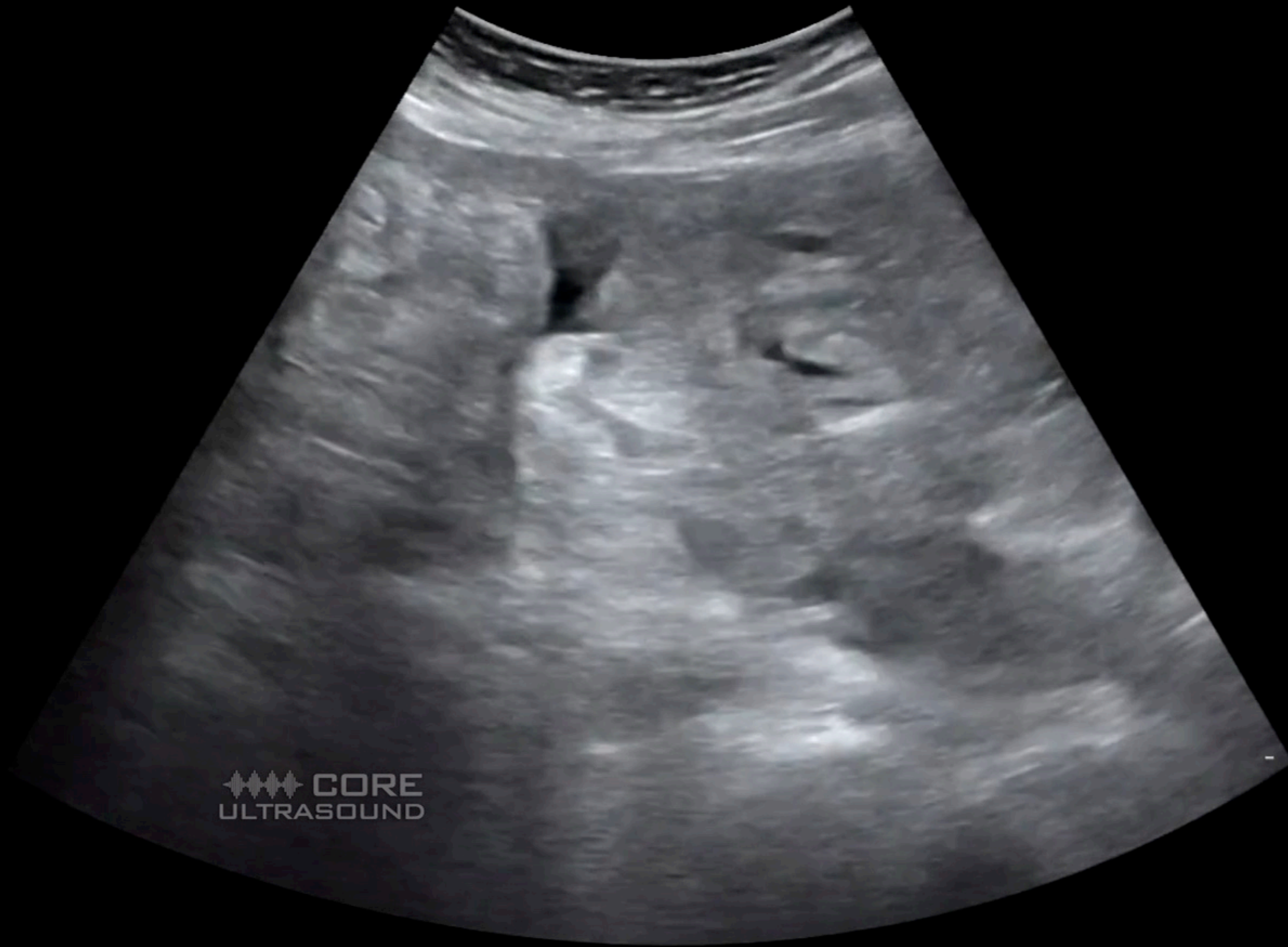

 **CORE**
ULTRASOUND



24F

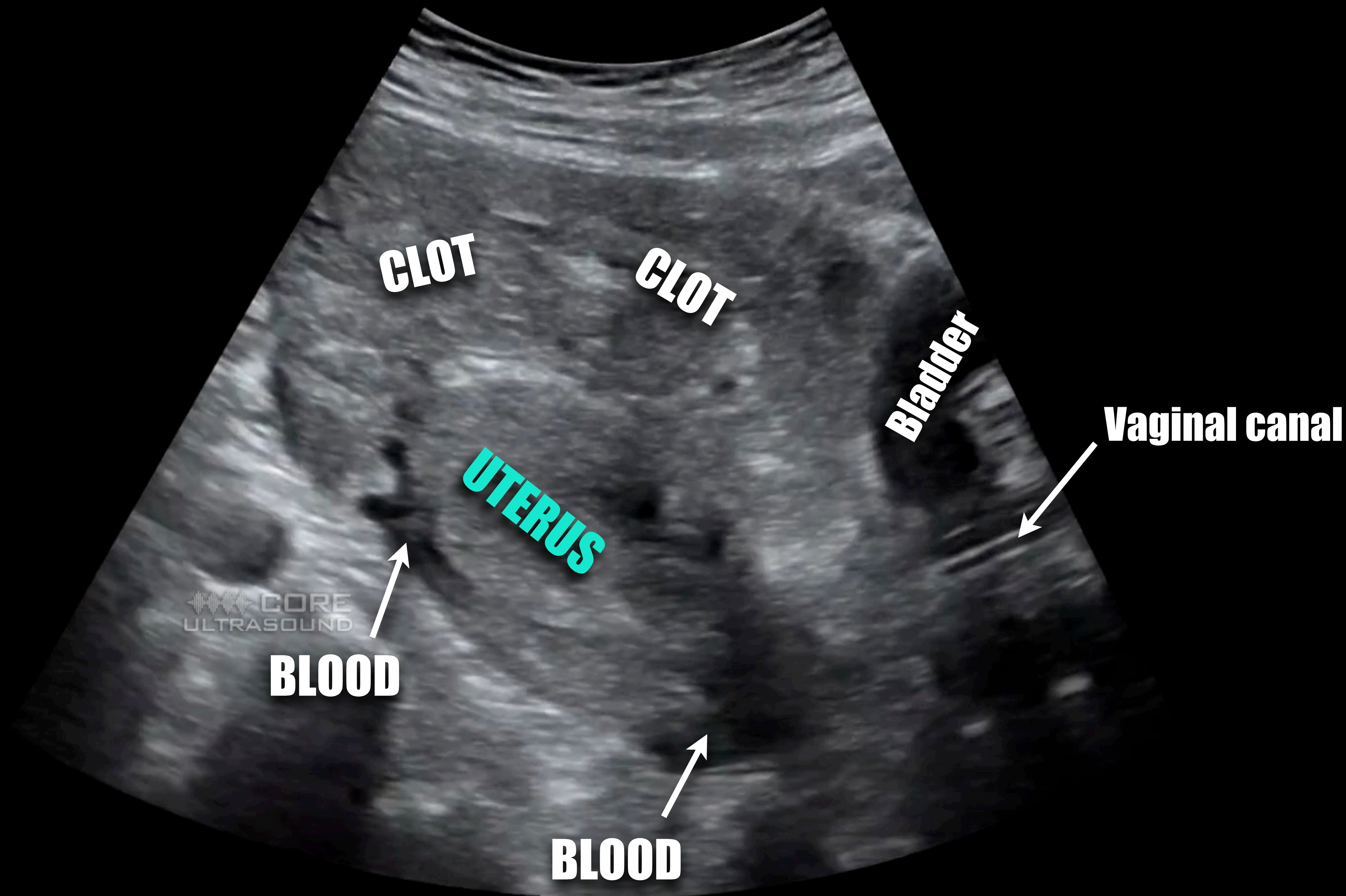
“Lower abdo pain”



◆◆◆ CORE
ULTRASOUND

A grayscale B-mode ultrasound image showing a longitudinal view of a fetal spine. The vertebrae are visible as a series of curved, echogenic lines. A watermark is present in the lower-left quadrant of the image.

 CORE
ULTRASOUND



CLOT

CLOT

Bladder

Vaginal canal


UTERUS

CORE
ULTRASOUND

BLOOD

BLOOD

ECTOPIC PREGNANCY

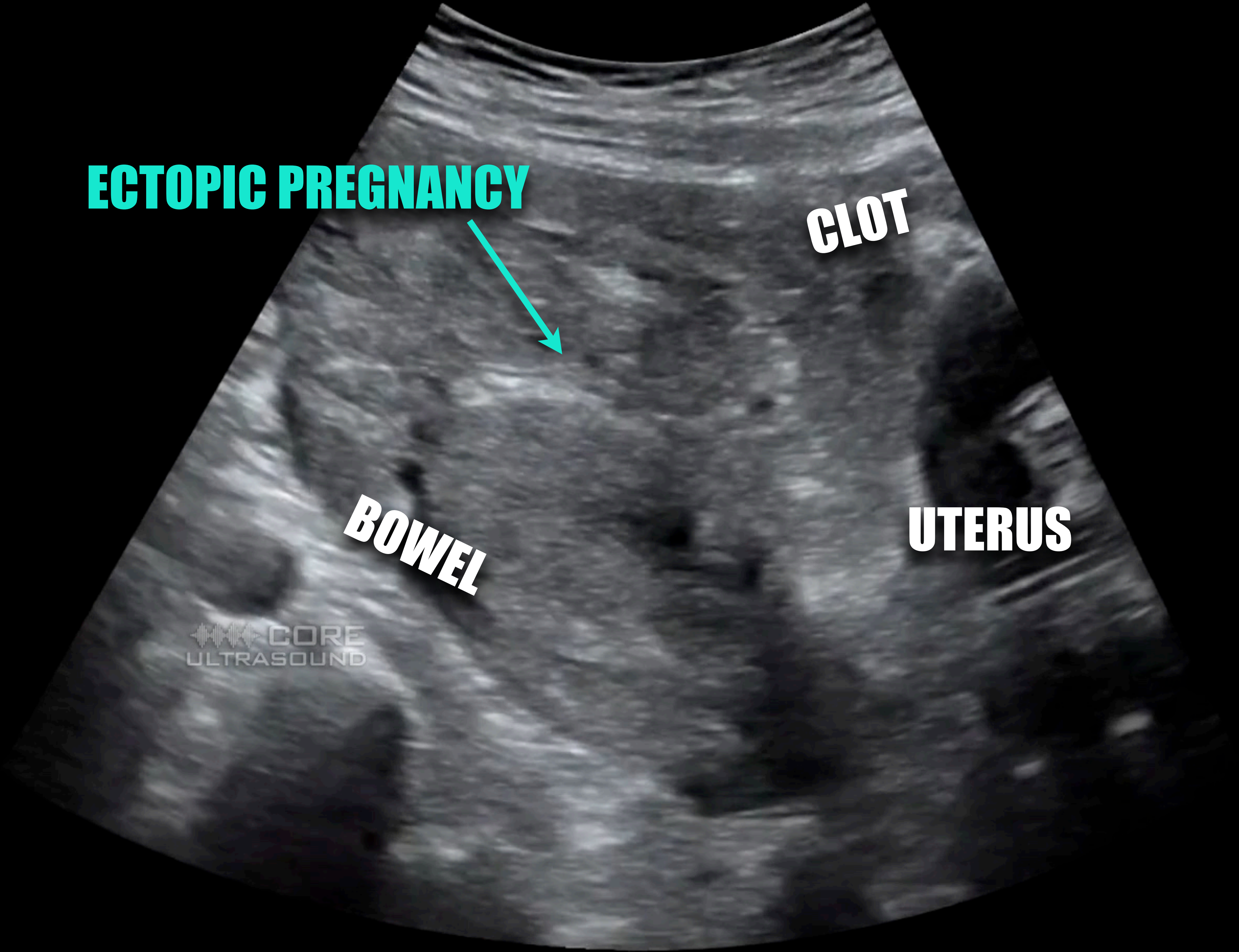


CLOT

BOWEL

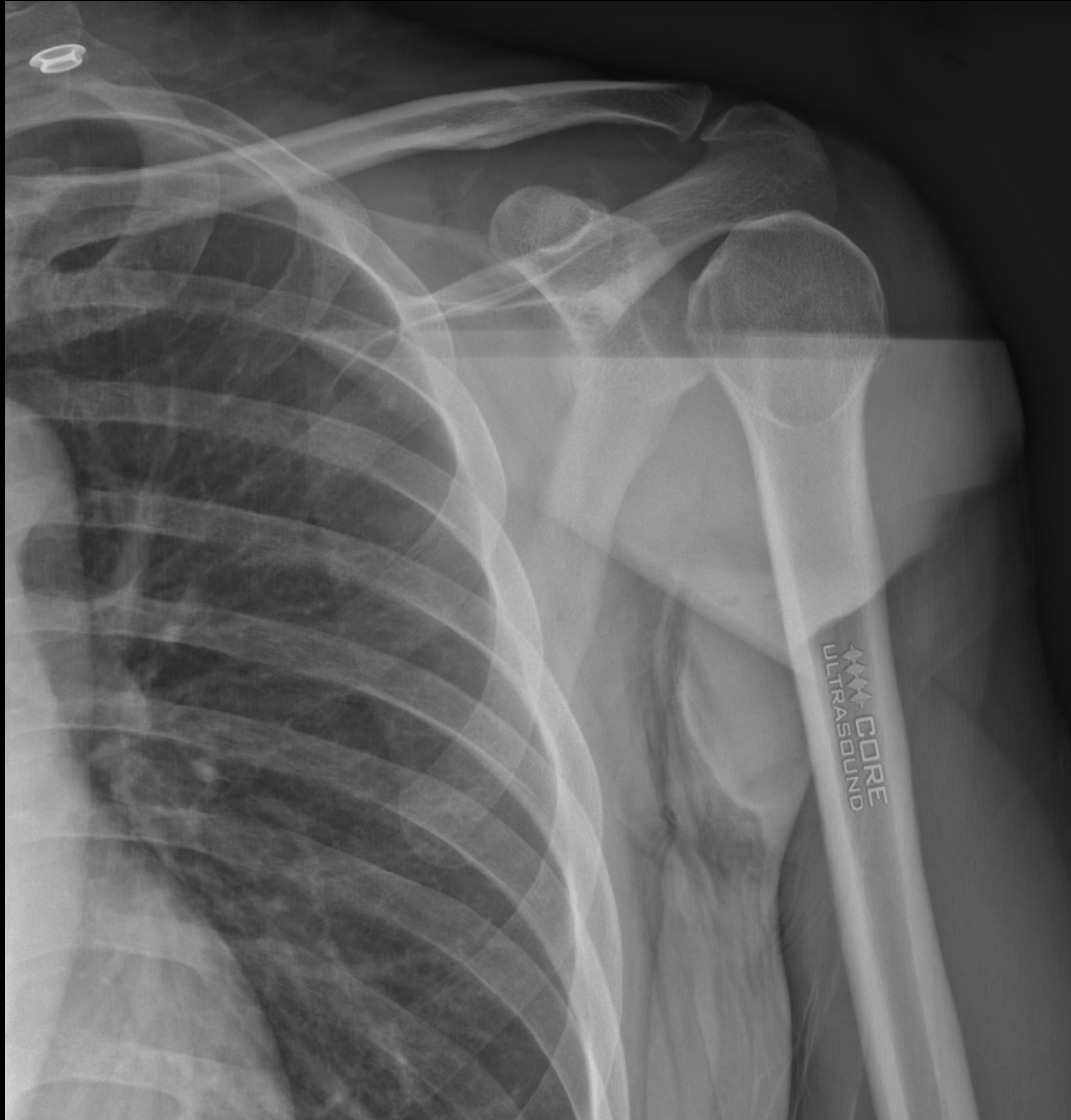
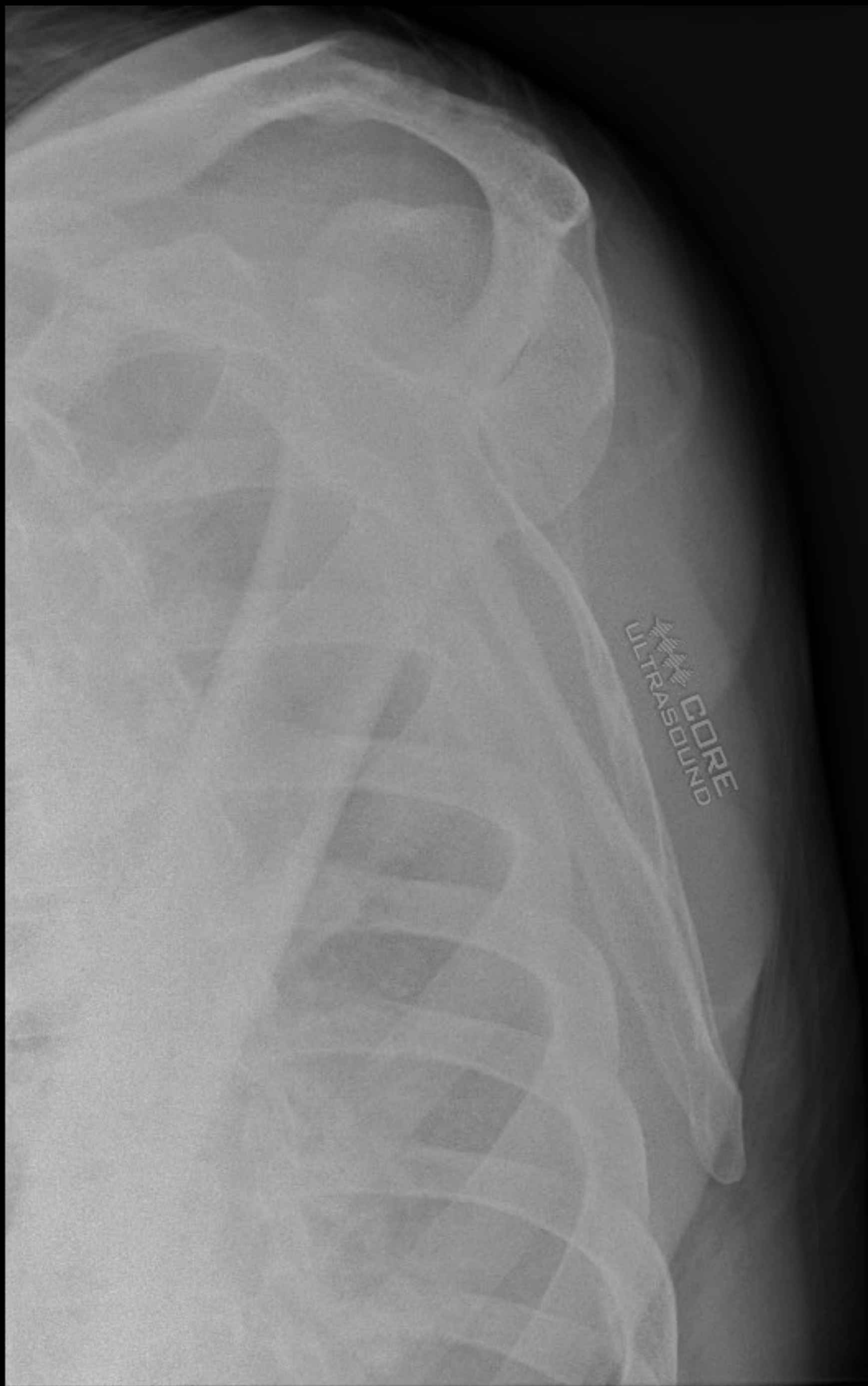
UTERUS

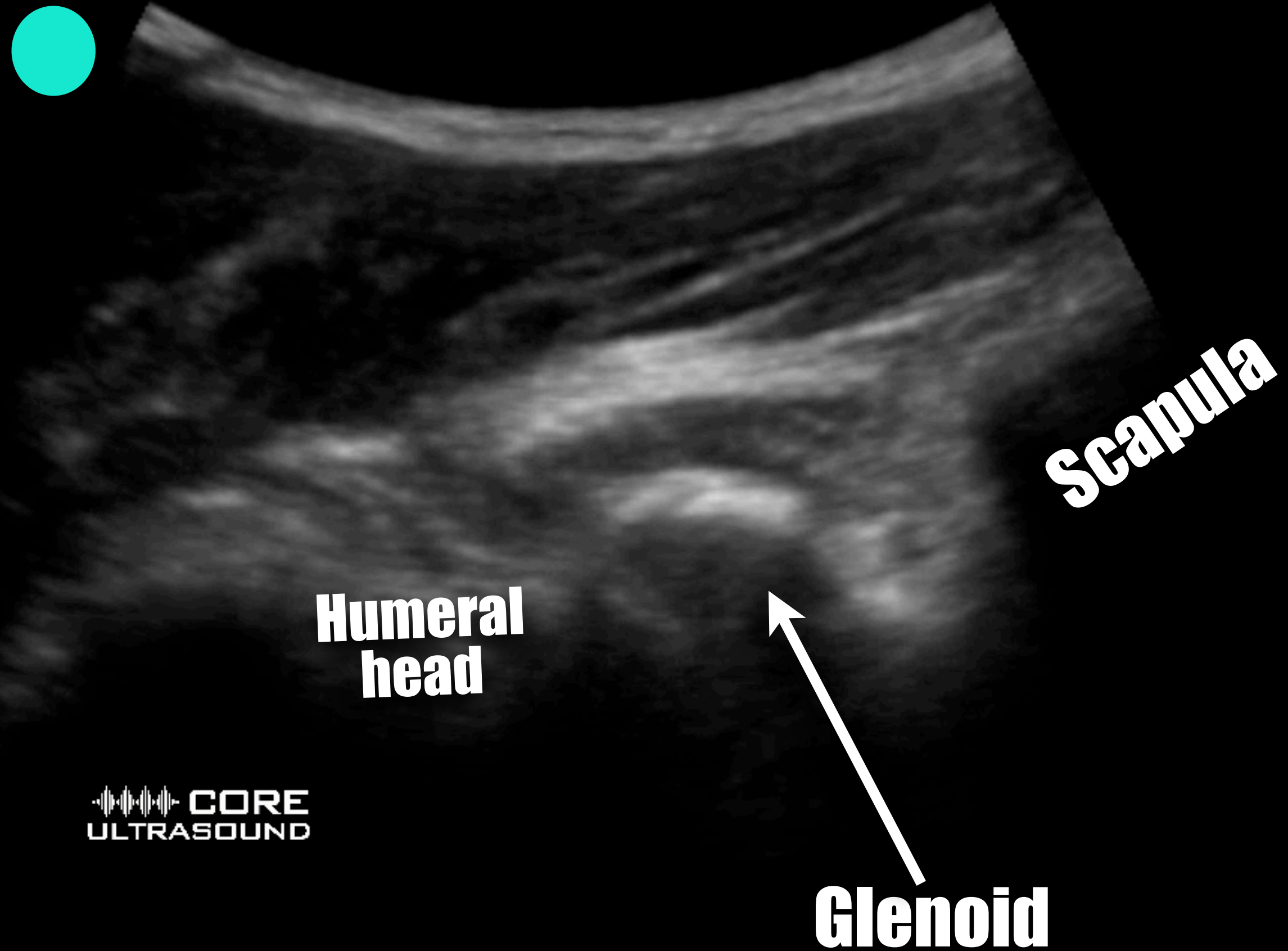

**CORE
ULTRASOUND**



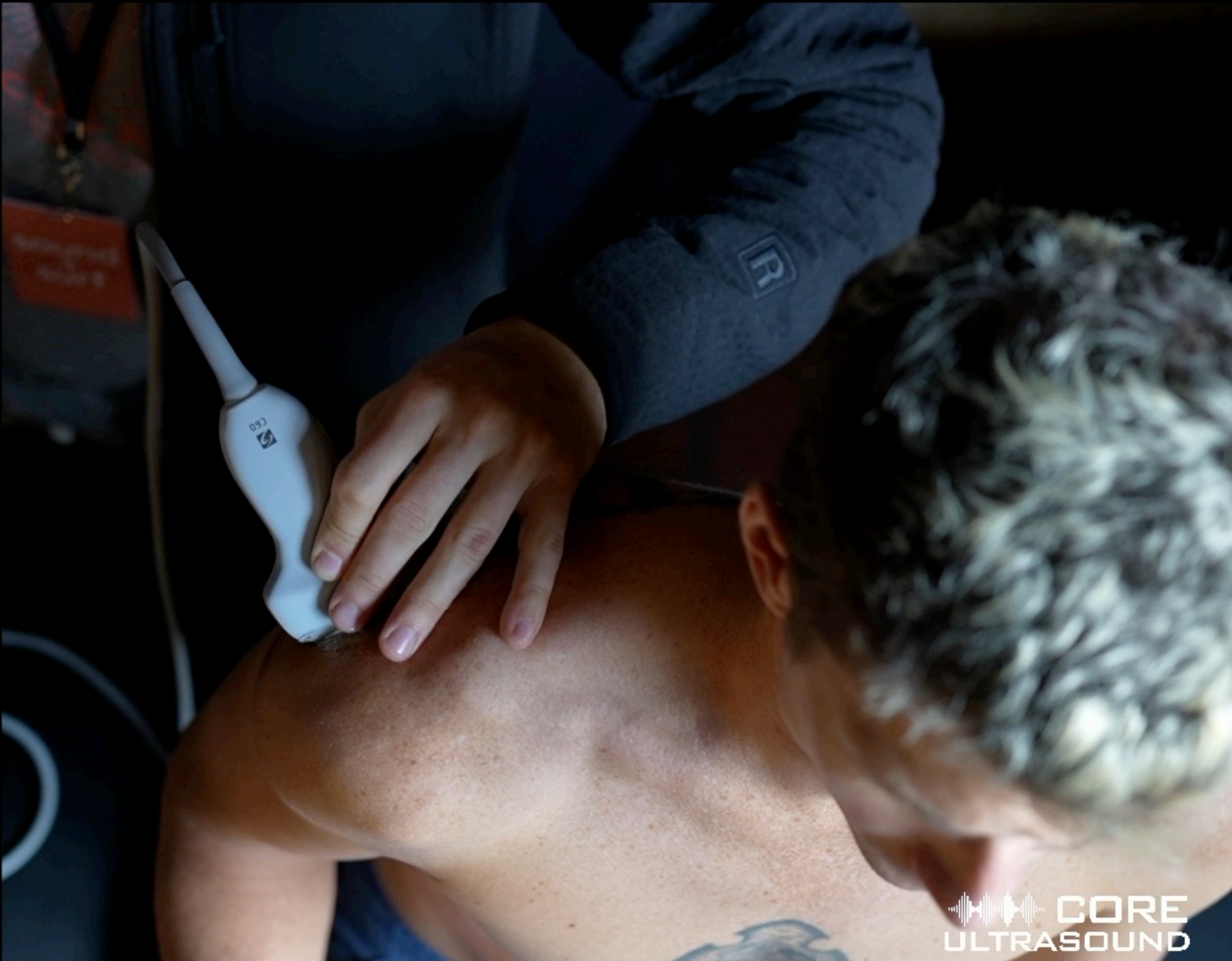52m

Shoulder pain





 CORE
ULTRASOUND

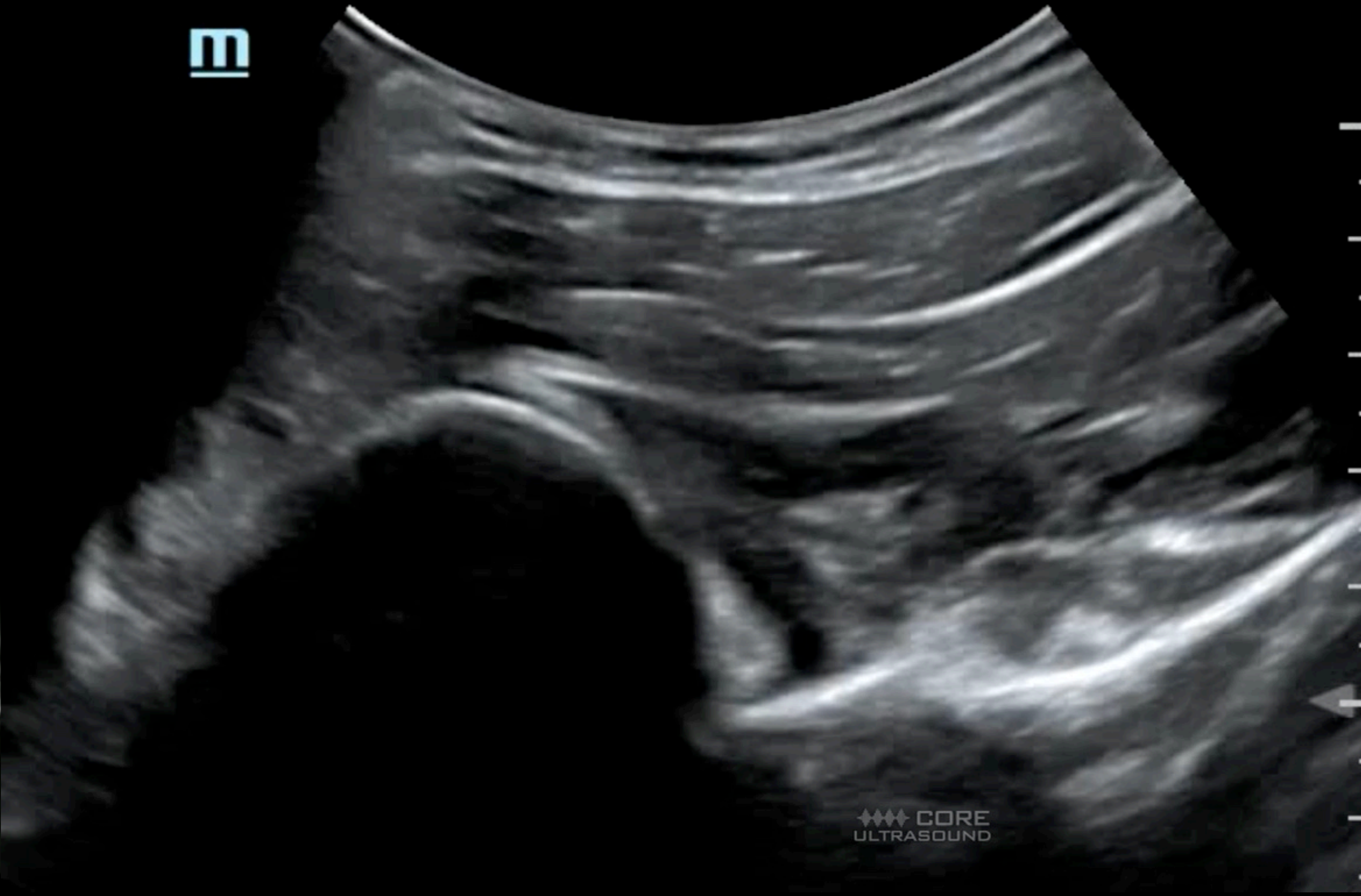
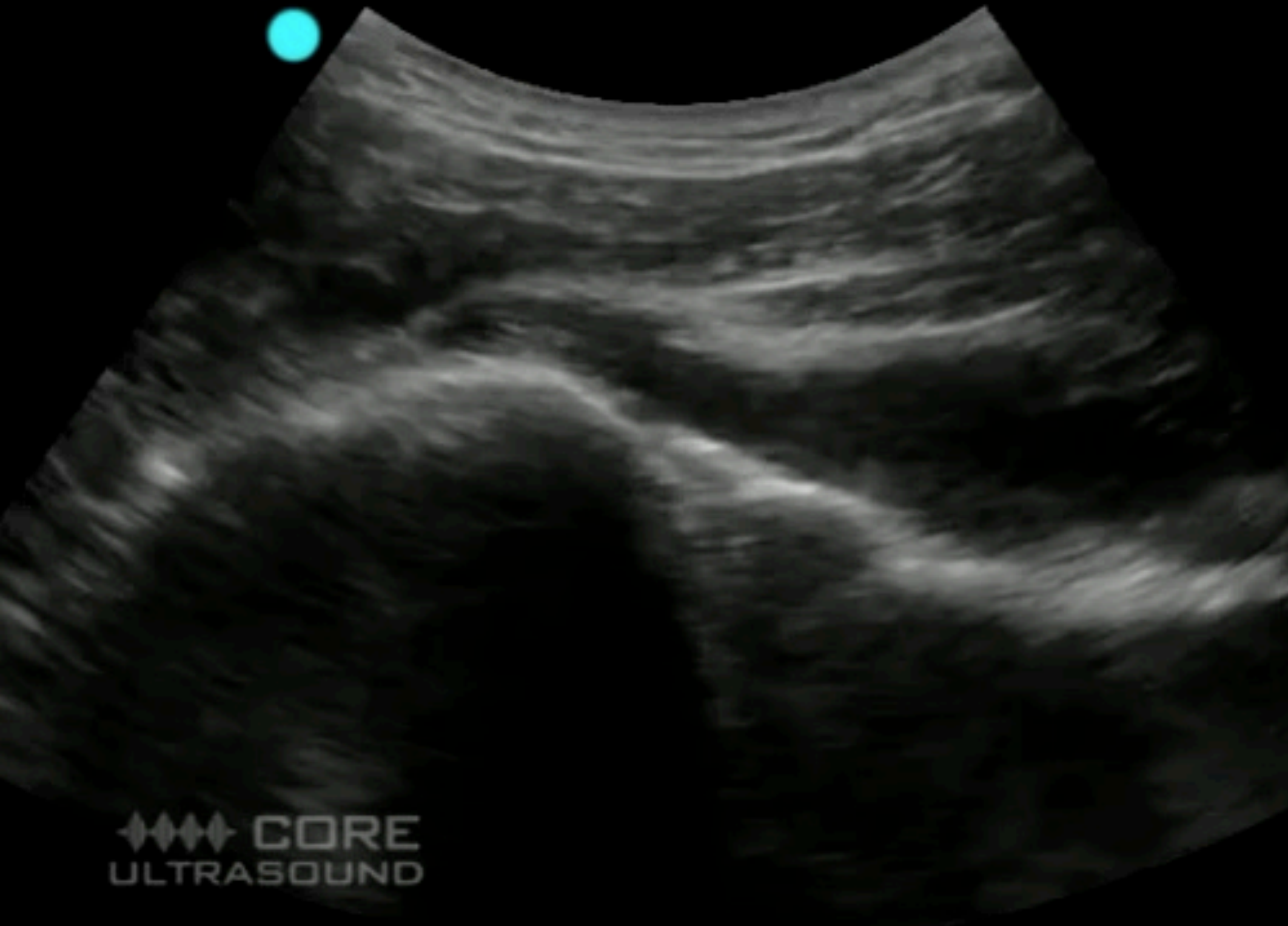


 CORE
ULTRASOUND

IN

NOT IN

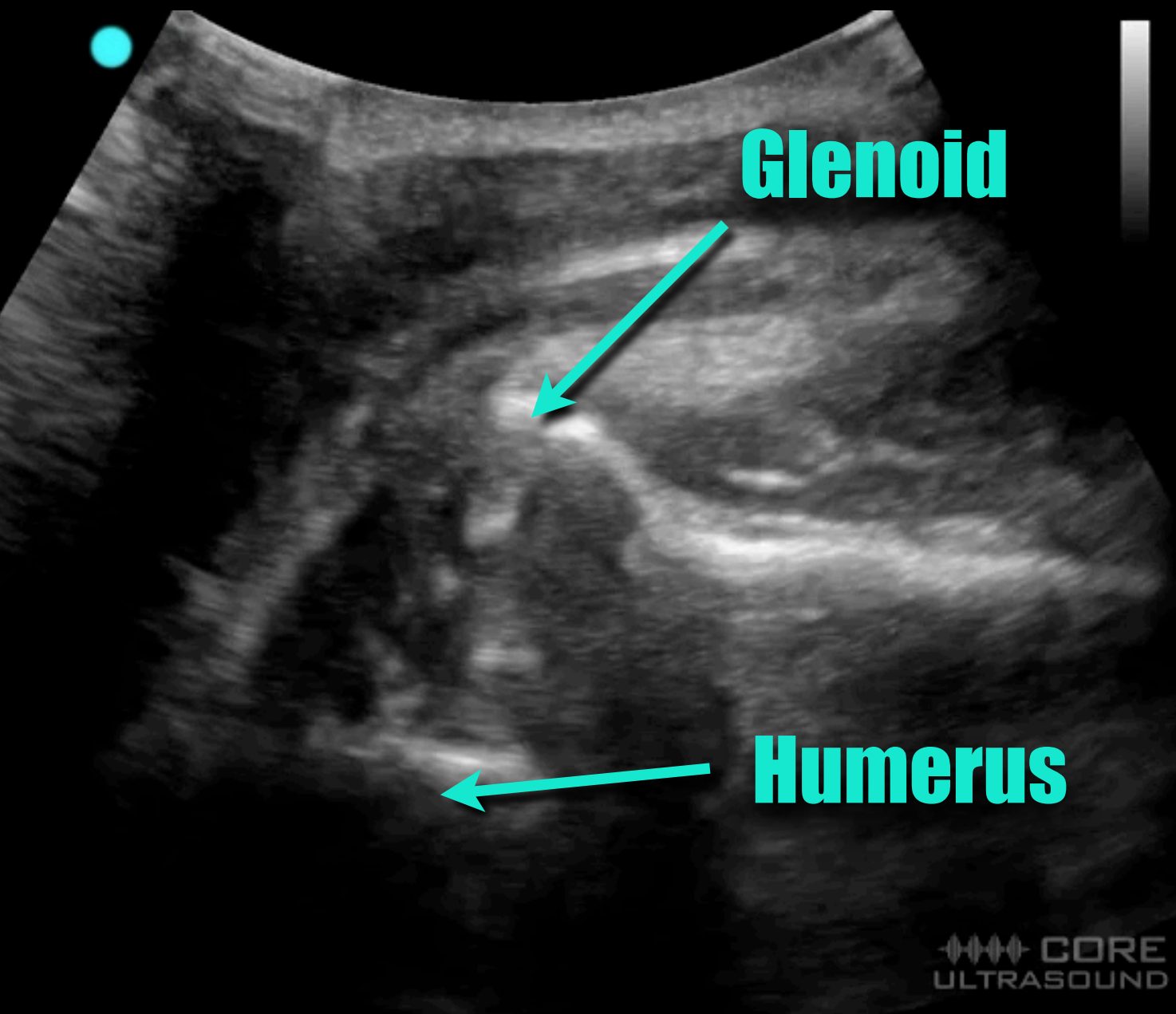
m



◆◆◆ CORE
ULTRASOUND

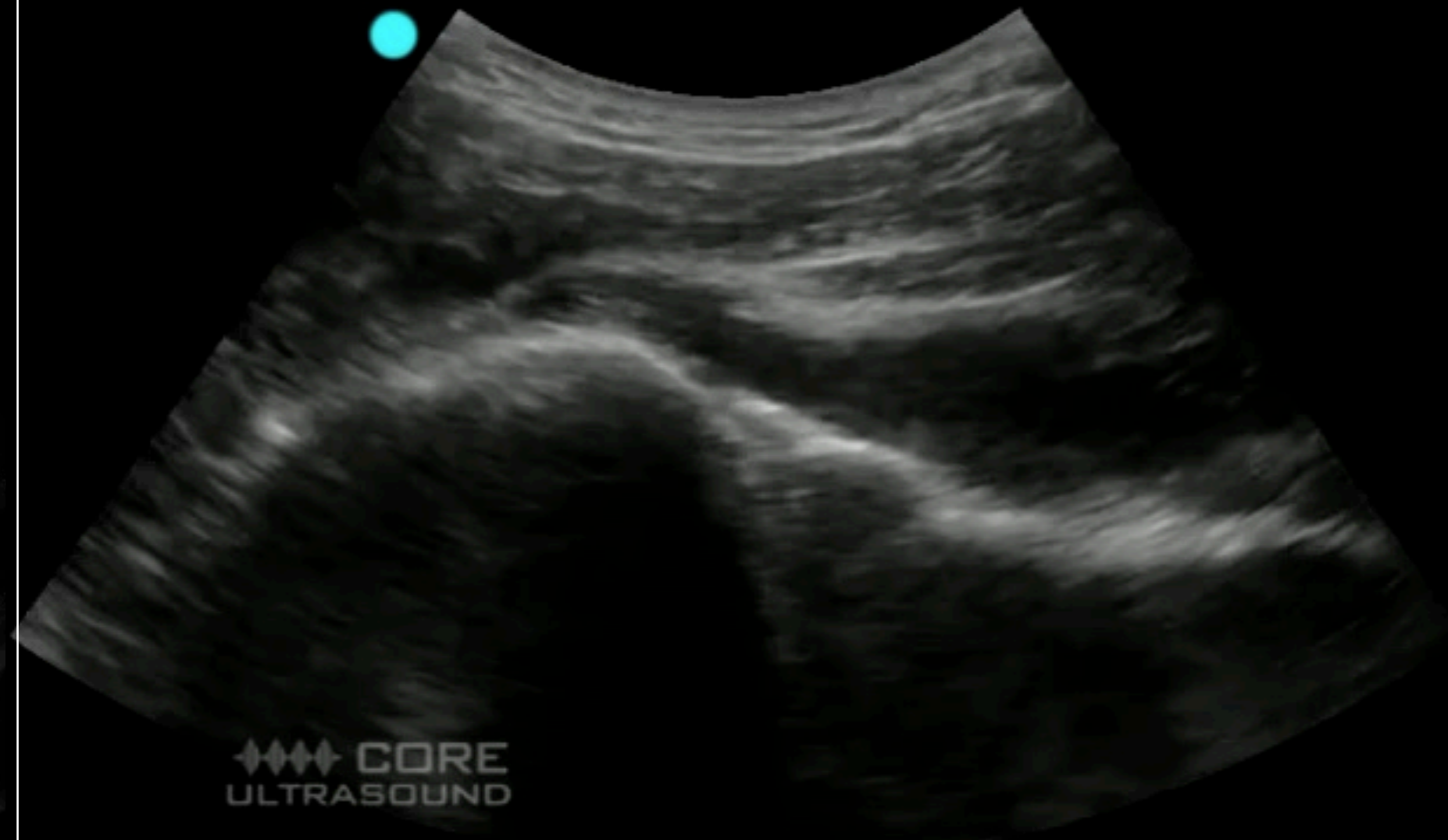
◆◆◆ CORE
ULTRASOUND

NOT IN

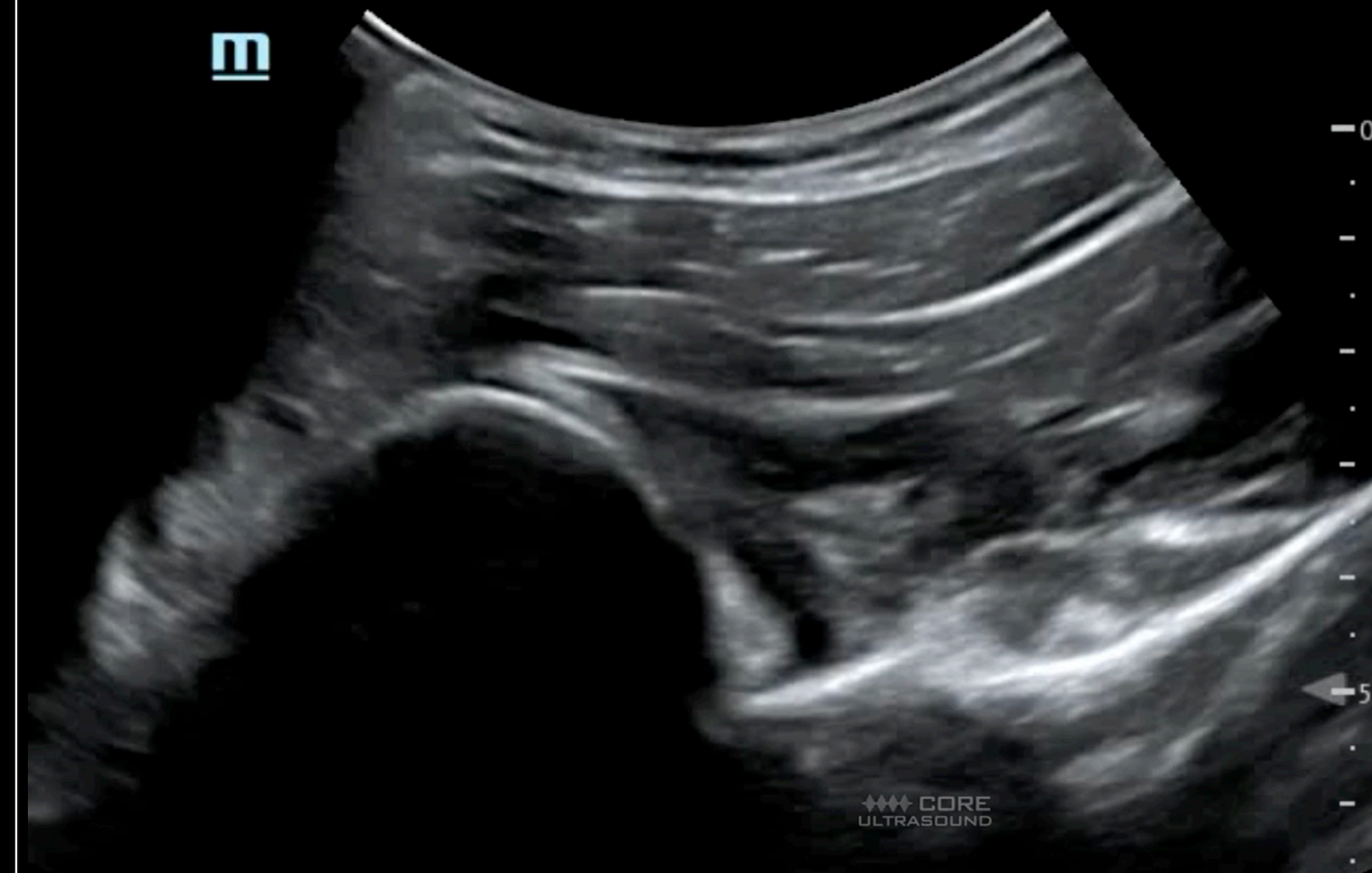


Anterior

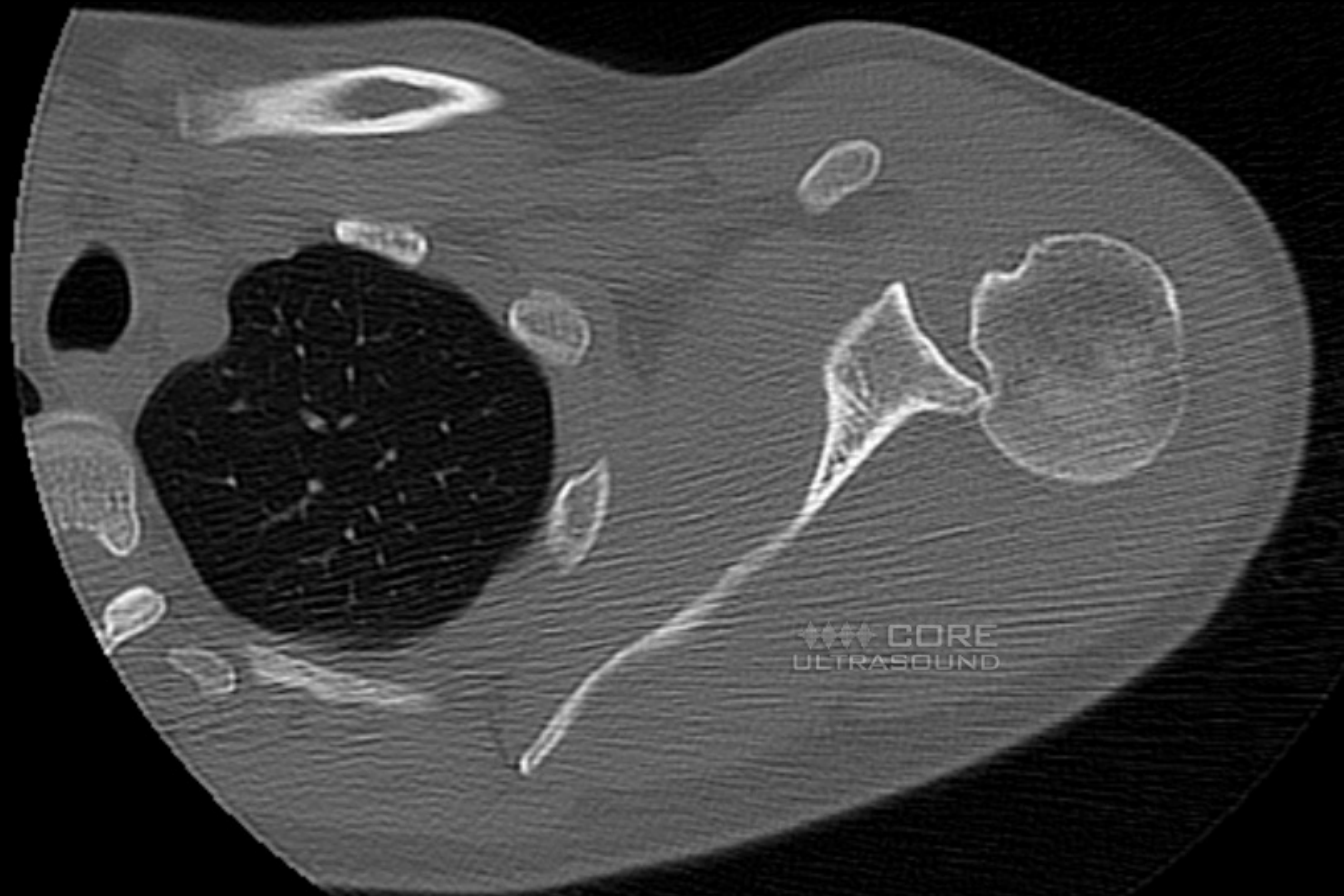IN



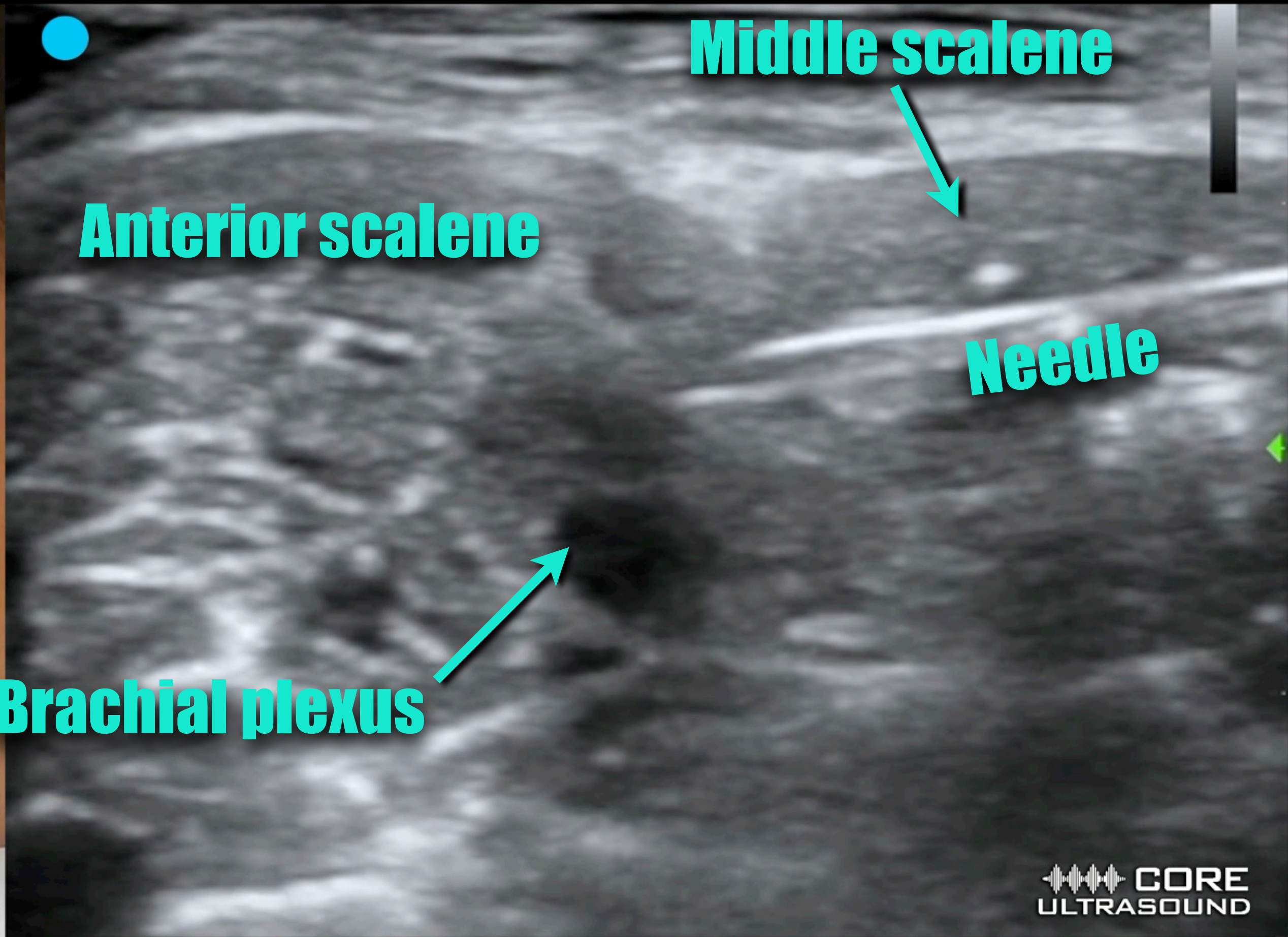
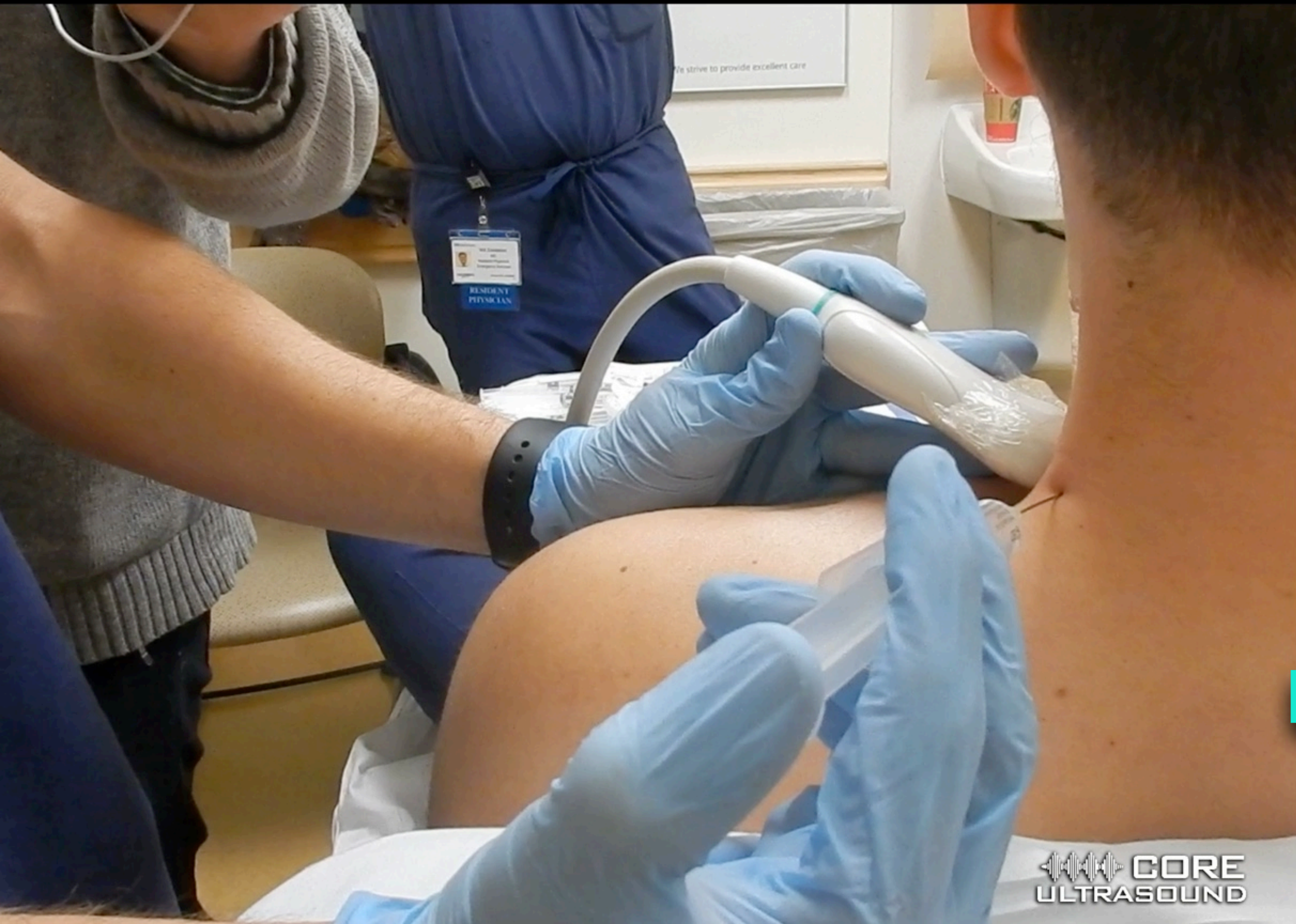NOT IN

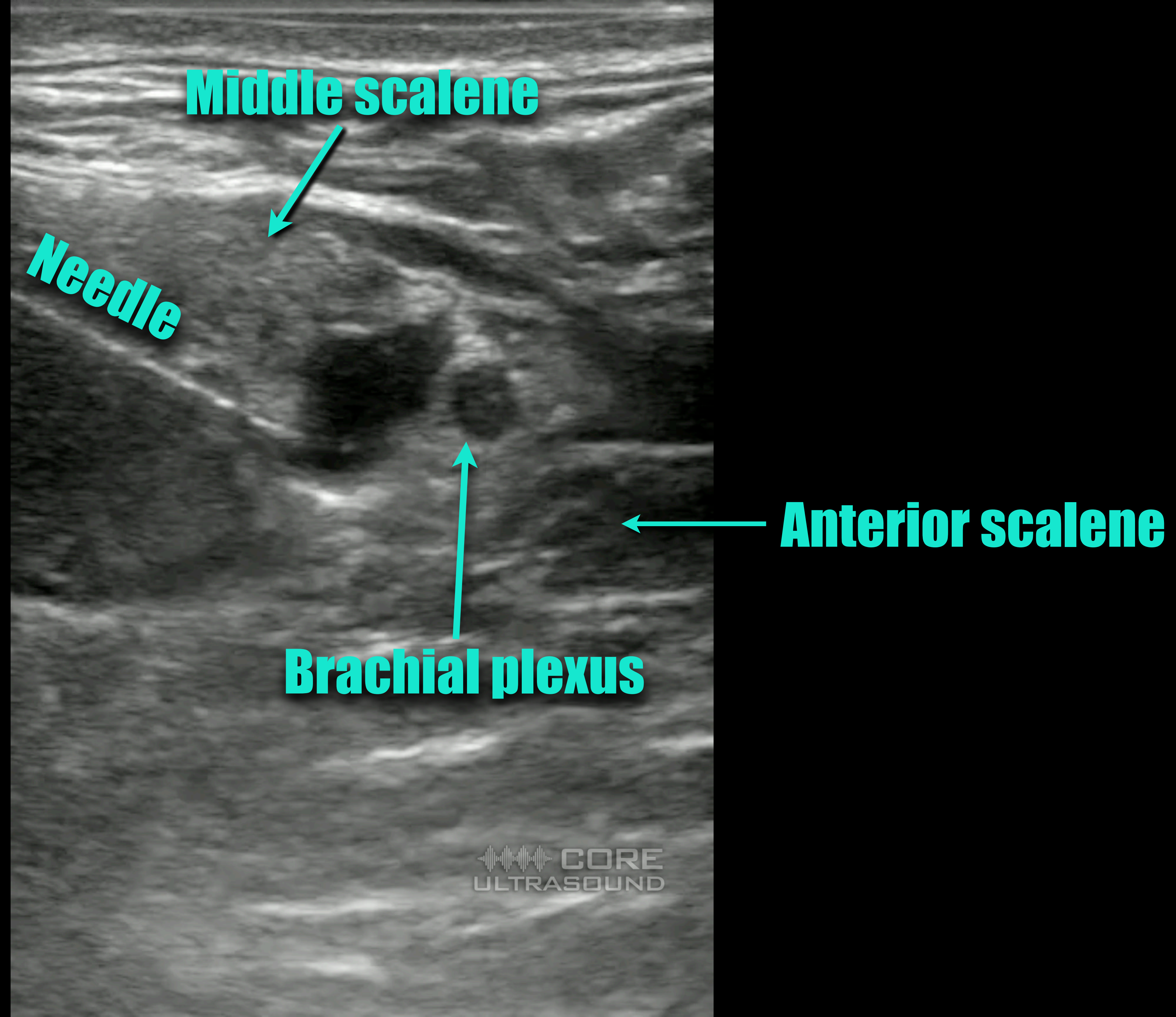


Posterior



◆◆◆◆ CORE
ULTRASOUND





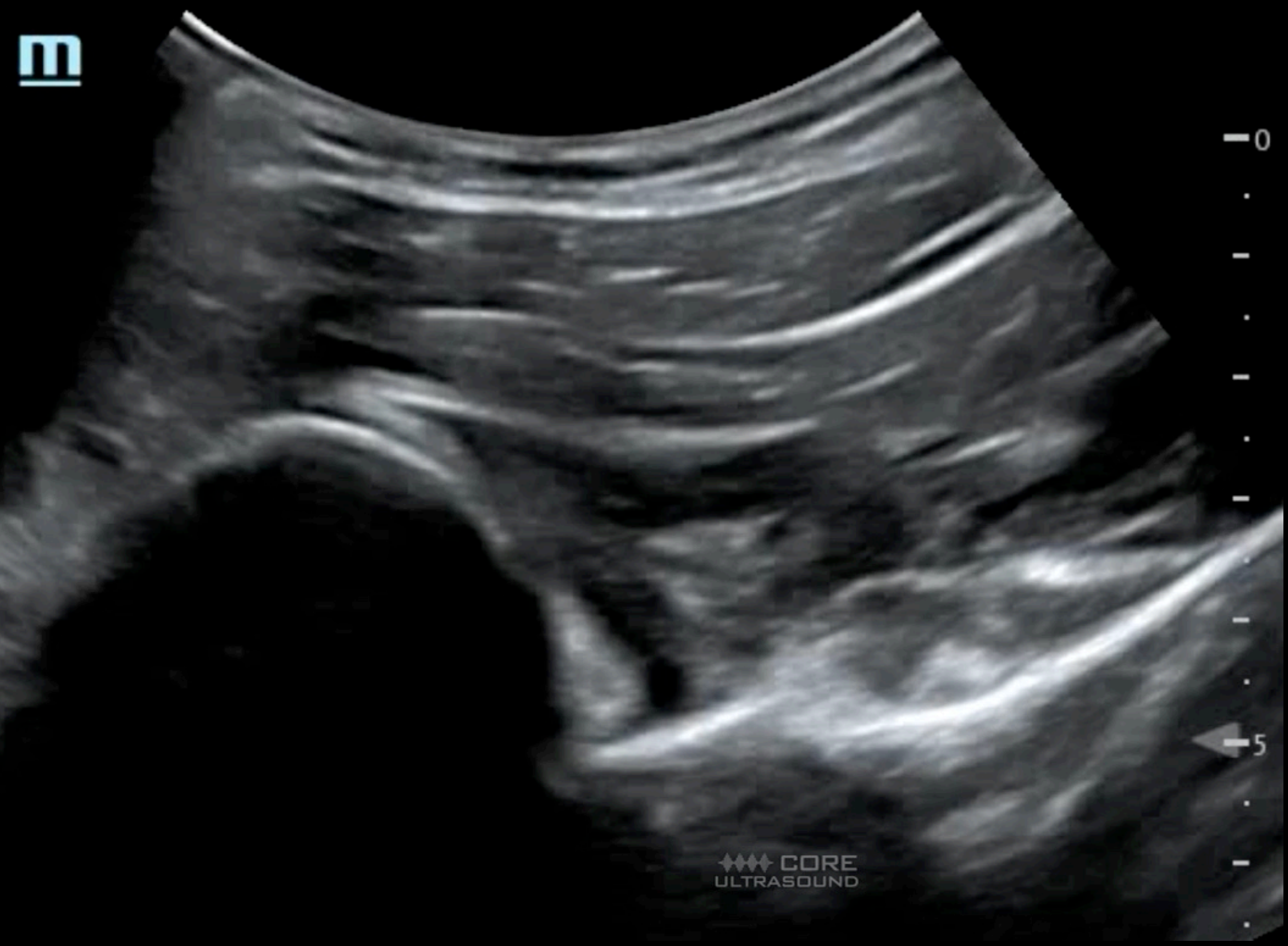Middle scalene

Needle

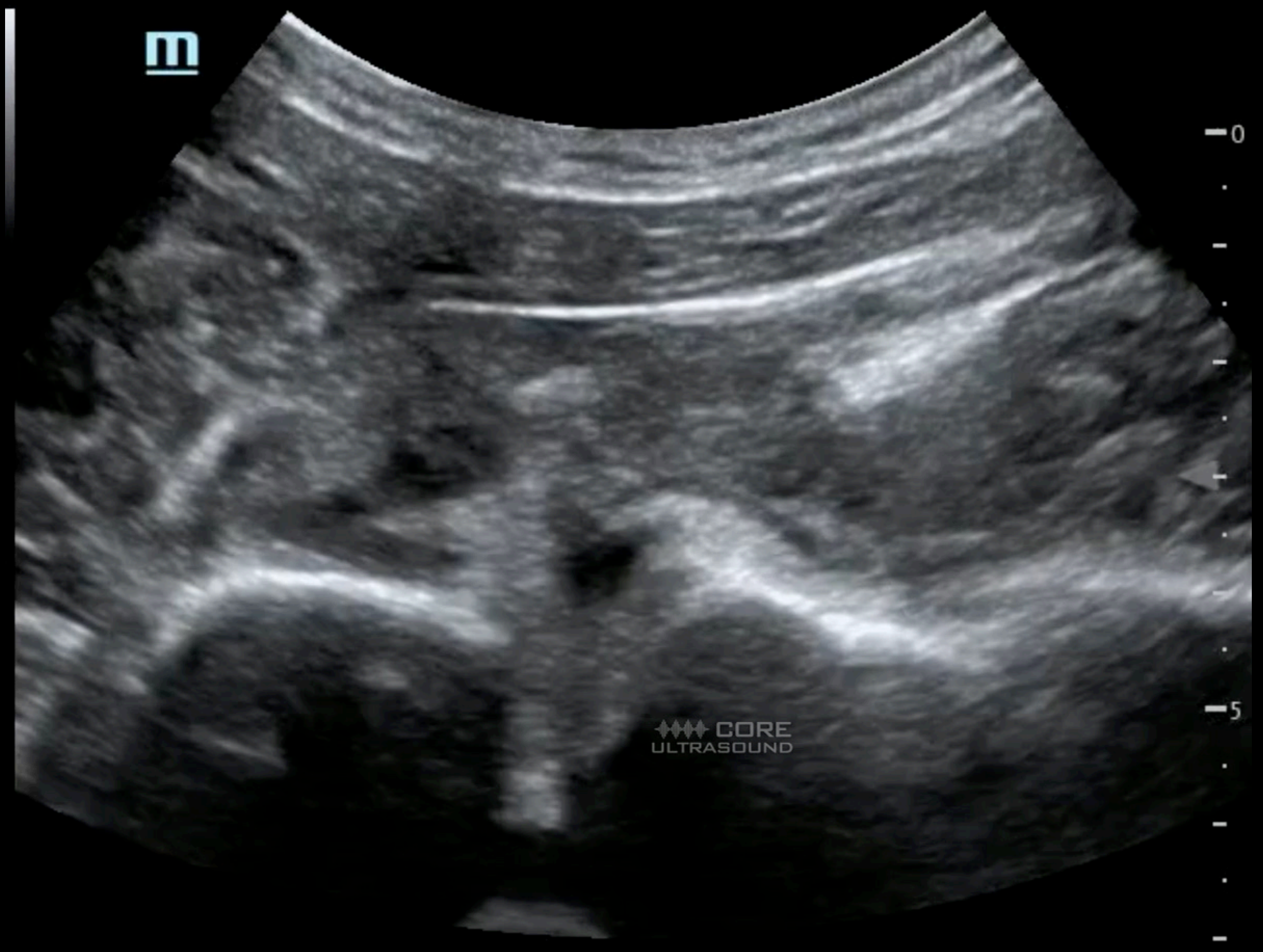
Anterior scalene

Brachial plexus

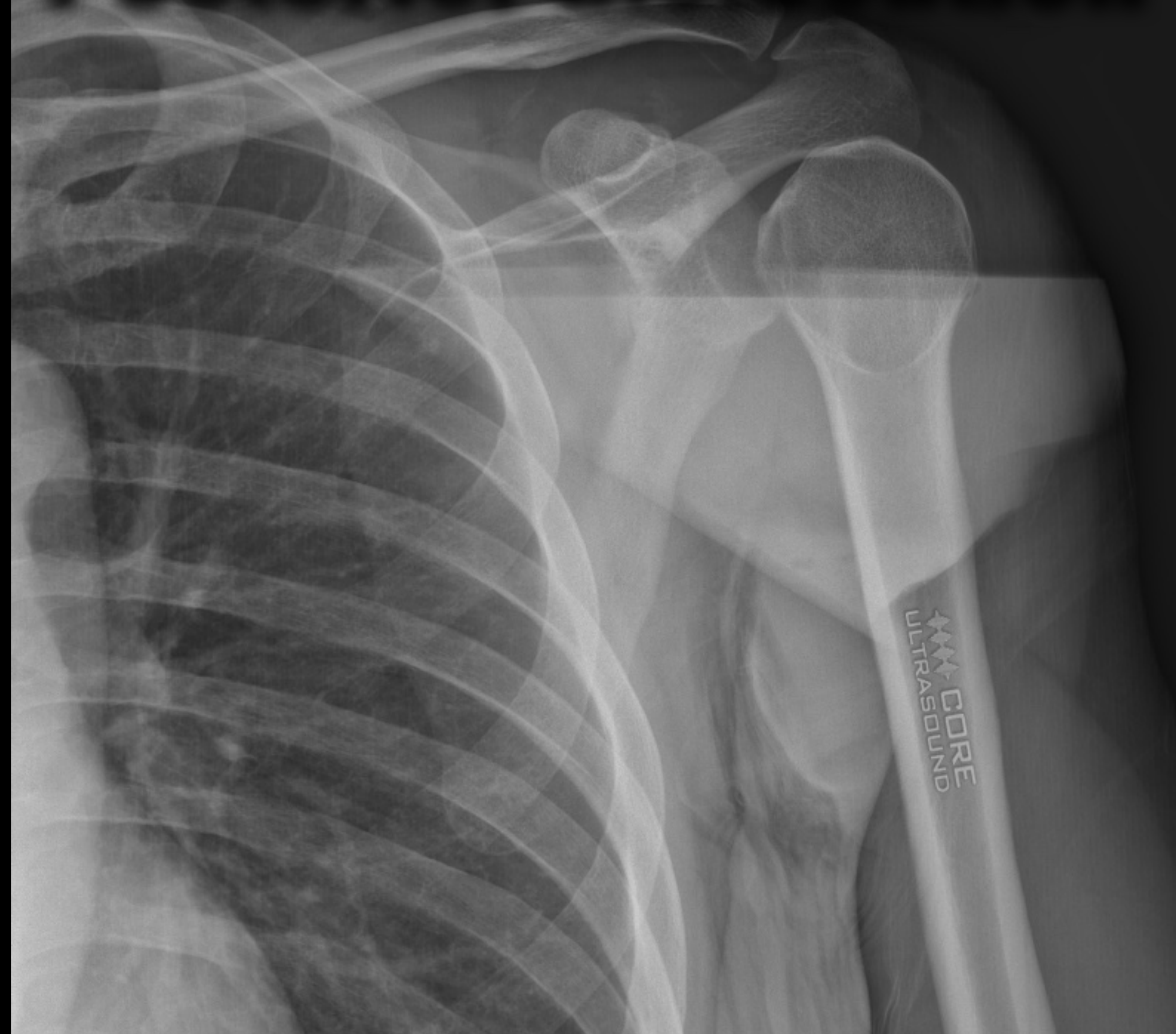
Before



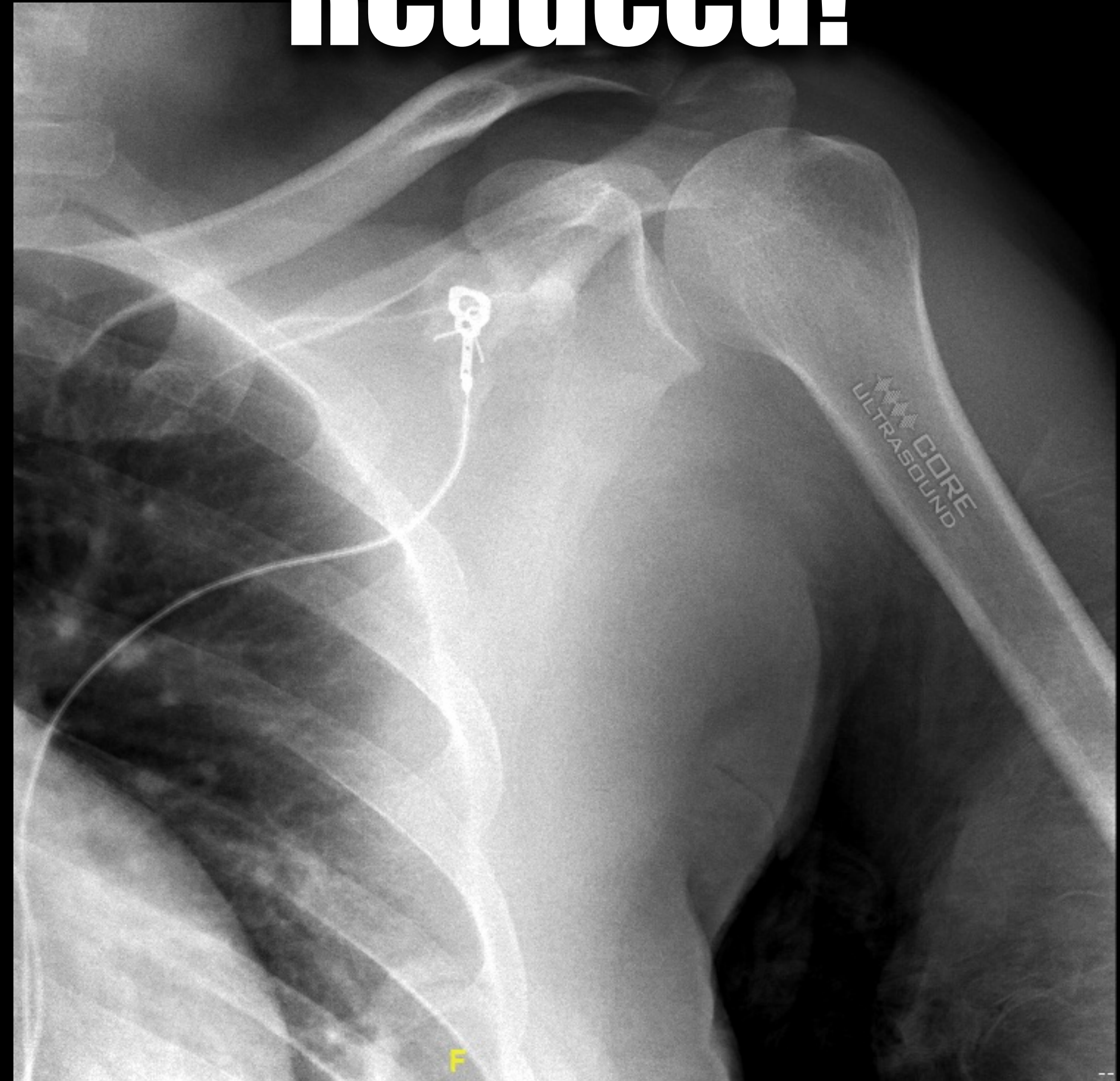
After



Posterior dislocation



Reduced!



35 m

SOB

m

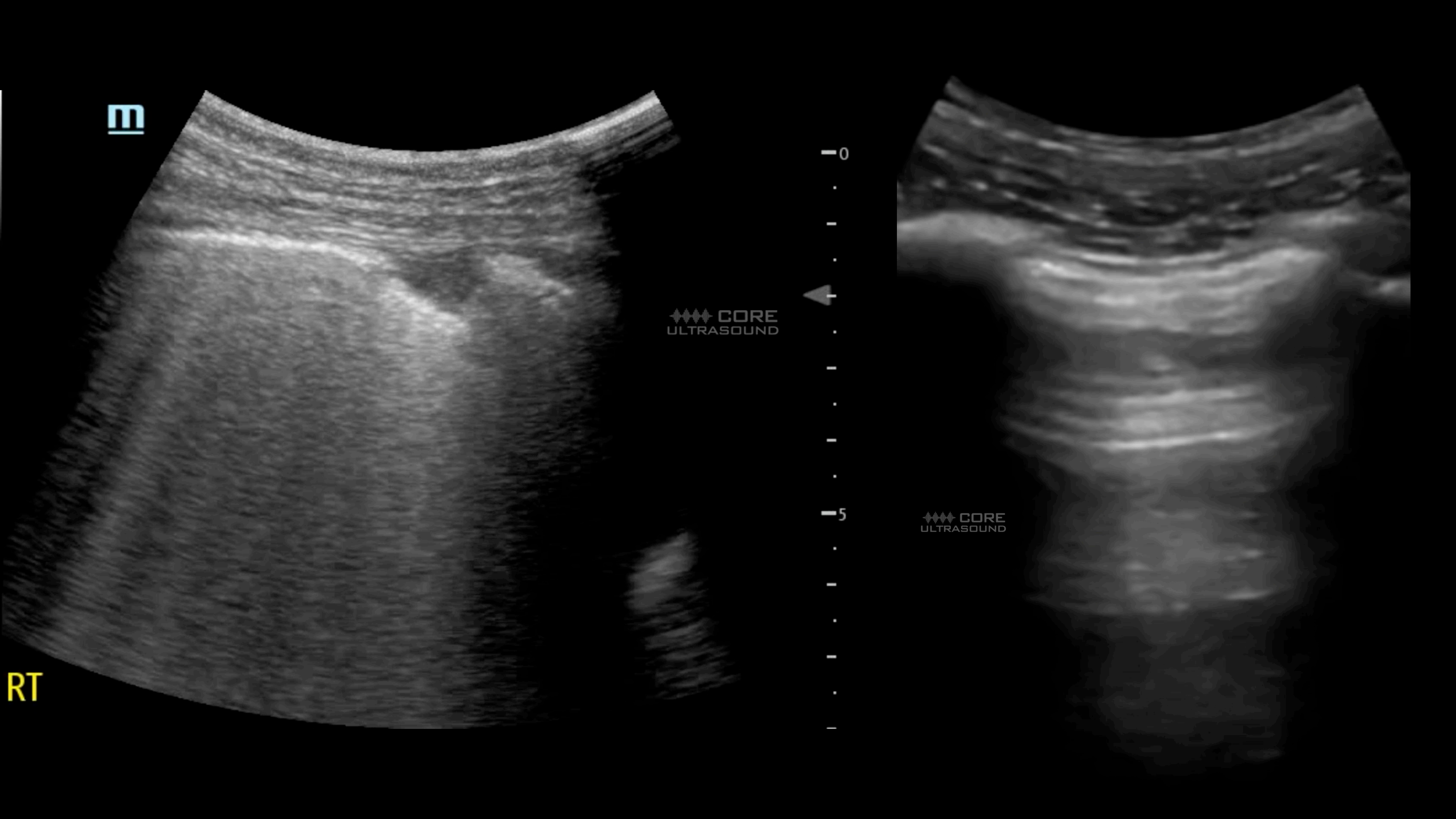
RT

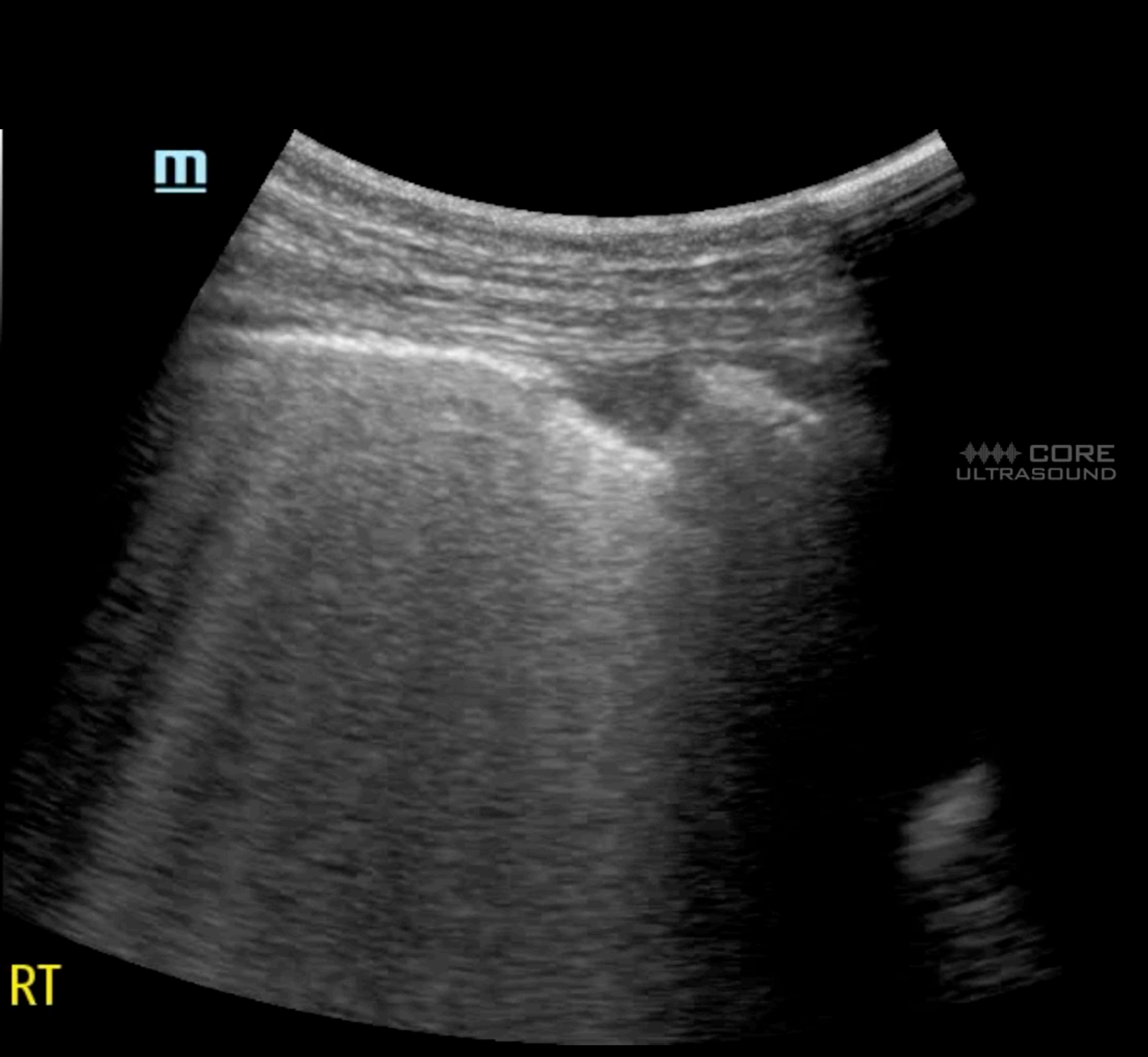
CORE
ULTRASOUND

0

5







DDX

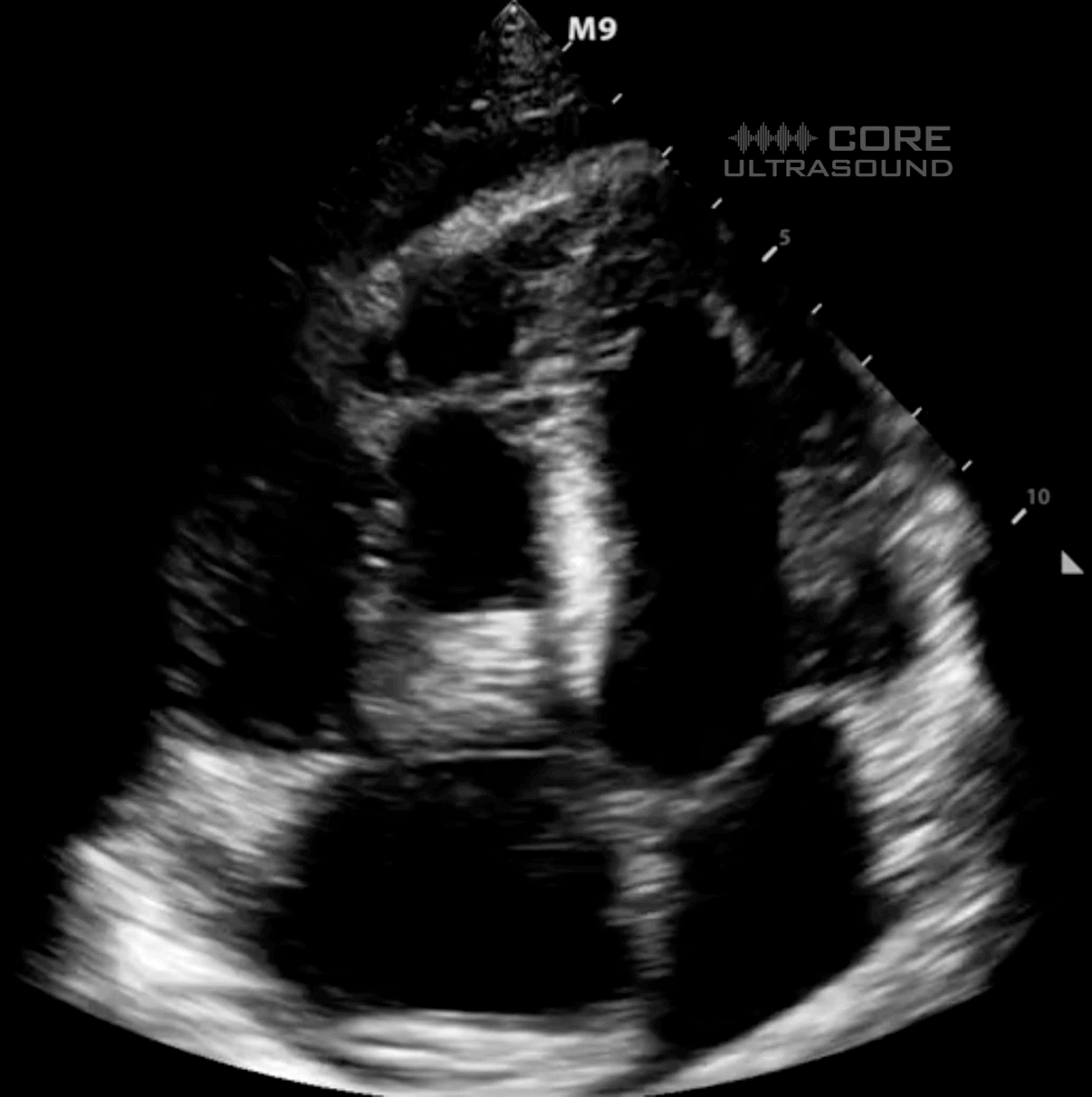- Viral pneumonia**
- Bacterial pneumonia**
- Pulmonary embolism**
- Atelectasis**
- Pulmonary contusion**
- Septic embolus**
- Cancer**

M9

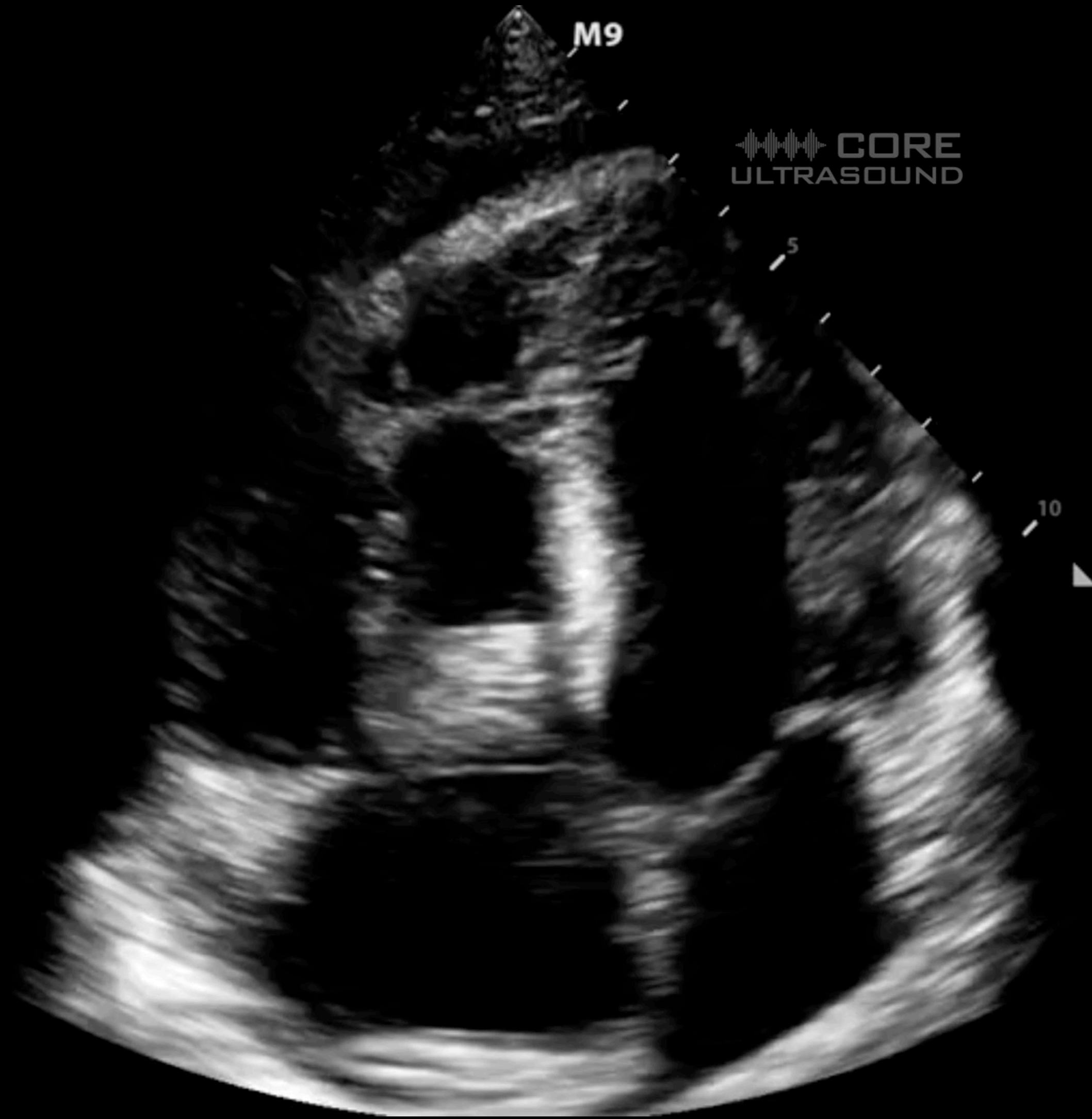CORE
ULTRASOUND

5

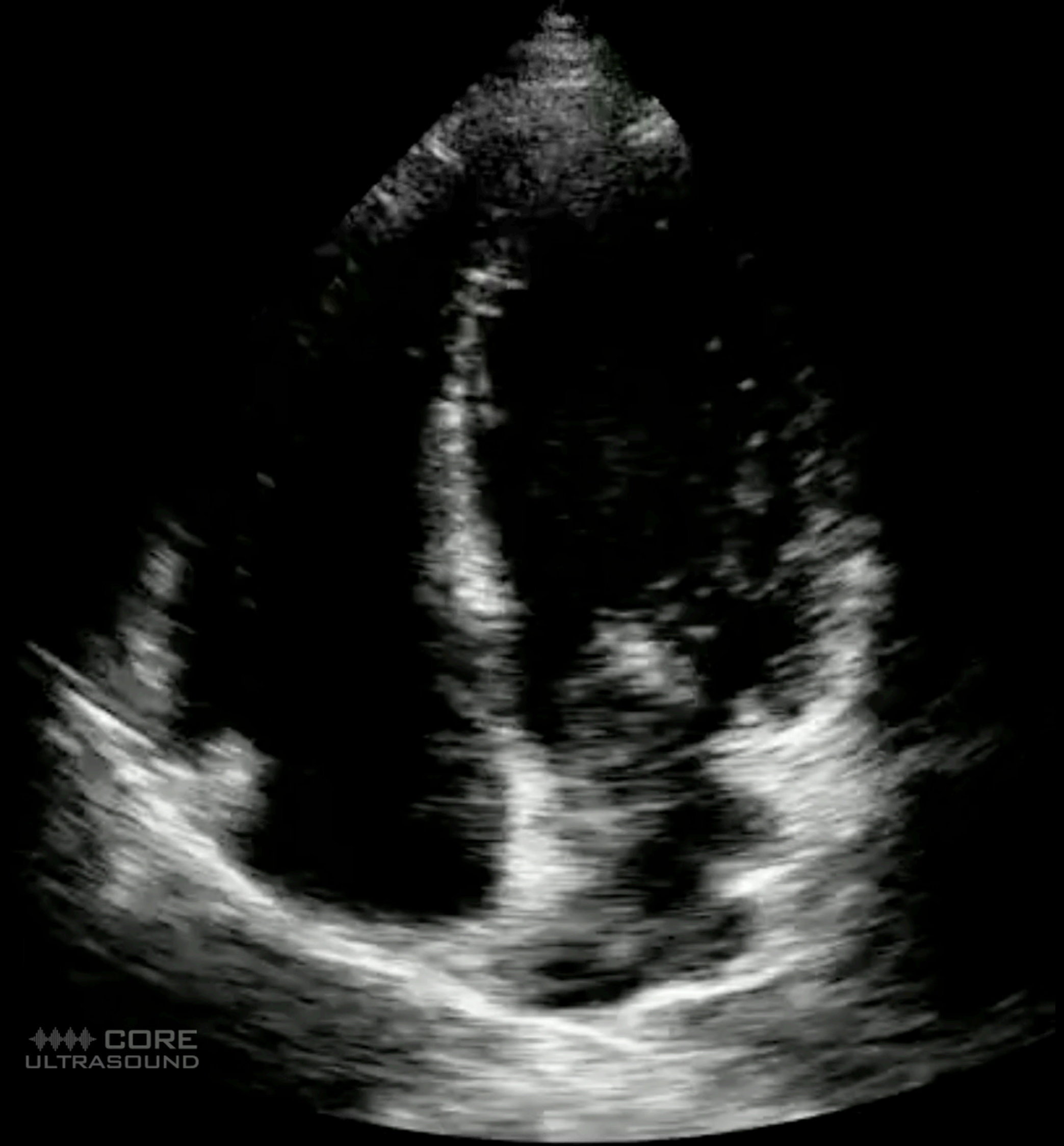10



Endocarditis



Not endocarditis



END



CORE

ULTRASOUND

LEARN • EXPLORE • SHARE



@COREULTRASOUND
ULTRASOUNDPODCAST@GMAIL.COM